

## **Ewing's Sarcoma of Right Lung in a 32 Years Old Male Patient**

Bidisha Ghosh Naskar, MD Radiotherapy, IPGMER, Kolkata

Swapan Kr Mallick, MD Radiotherapy, Malda Medical College

Harris M Sepai, MD Radiotherapy, IPGMER, Kolkata

Kaustav Chatterjee, MD Radiotherapy, Post Graduate Trainee, IPGMER, Kolkata

**Correspondence Author:** Swapan Kr Mallick, MD Radiotherapy, Malda Medical College, India

**Type of Publication:** Case Report

**Conflicts of Interest:** Nil

### **Abstract**

Ewing's sarcoma is the second most common primary osseous malignancy in children and young adults. However, infrequently, it can arise outside the skeletal system; rarer still, it can originate within the lung parenchyma. Thirty two year old male patient who presented with three months history of cough and gradual onset respiratory distress followed by pain and heaviness of right hemithorax. On imaging revealed right sided mid lobe mass and pleural effusion. Trucut biopsy from the lung lesion showed small, blue, round or ovoid cells.

Immunohistochemistry was done to establish the diagnosis. It reveals the cells positive TTF1, Calretinin. The Ki-67 labelling index is about 95%. The overall picture is for CD99, FLI1, CD 56 (focal) and negative for Chromogranin, Desmin, S100, EMA, compatible with PNET/ Ewing's sarcoma. With diagnosis of Ewing's sarcoma, VAC (Vincristine, Adriamycin, Cyclophosphamide) alternating with IE (Ifosfamide, Etoposide) chemotherapy regimen was started. Patient completed 17 cycles of chemotherapy the disease is

clinically and Radiologically responding. Patient was sent to cardiothoracic department for surgical opinion. Patient underwent surgical resection followed by radiotherapy and now doing well at 2 months follow-up.

**Key-words:** Ewing's sarcoma, Extra-osseus, Pulmonary mass, chemotherapy, surgical resection, radiotherapy.

### **Key Messages**

Extraosseus Ewing's sarcoma being rare and aggressive tumor, has no specific guidelines for treatment. Usually multimodality approach including neo-adjuvant chemotherapy followed by surgery and / or radiotherapy is the preferred approach in the few cases studied worldwide.

### **Introduction**

Ewing's sarcoma is a neuroectodermal tumour characteristically presenting during the second decade of life and arising from bone. The annual incidence is estimated to be 0.6 per million population.[1] Common locations include the axial skeleton, as well as the diaphyseal portion of long bones, most commonly those of the

lower extremities<sup>[2]</sup>. However, extraskeletal Ewing's sarcoma, first described in 1969<sup>[3]</sup>, represents a less frequent but histologically similar entity that can originate within a wide array of extraosseous/soft tissue locations, including the retroperitoneum, chest wall, or paravertebral space<sup>[4]</sup>. PNETs that arise in the lung parenchyma are extremely rare in adults. Here we are reporting a primary pulmonary PNET in an adult.

### Case History

A 32 year old male patient presented with three months history of cough and gradual onset respiratory distress followed by heaviness and pain of right hemithorax. He had no significant past medical history and was a non-smoker. Chest radiograph demonstrated right mid zone mass with right sided pleural effusion. Subsequent CECT scan of thorax revealed lobulated mass in right midzone compressing right main bronchus along with right hilar lymphadenopathy and right sided pleural effusion.

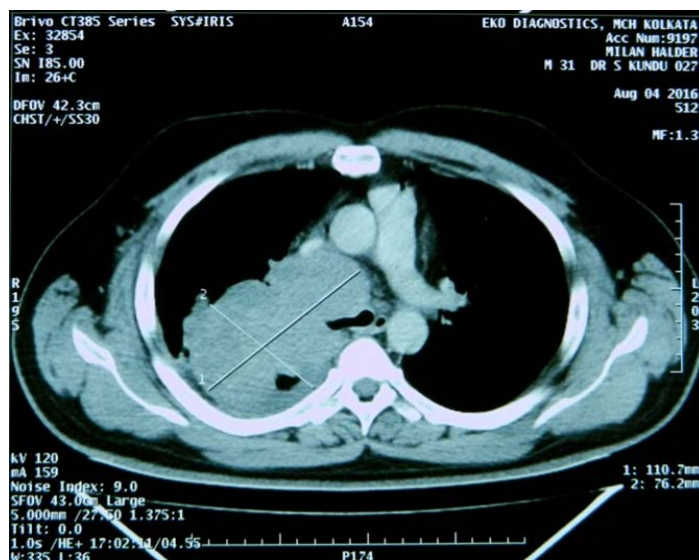


Figure 1a. Computed tomography of the chest

(Axial view) showing lobular mass at right mid zone encasing right main bronchus.

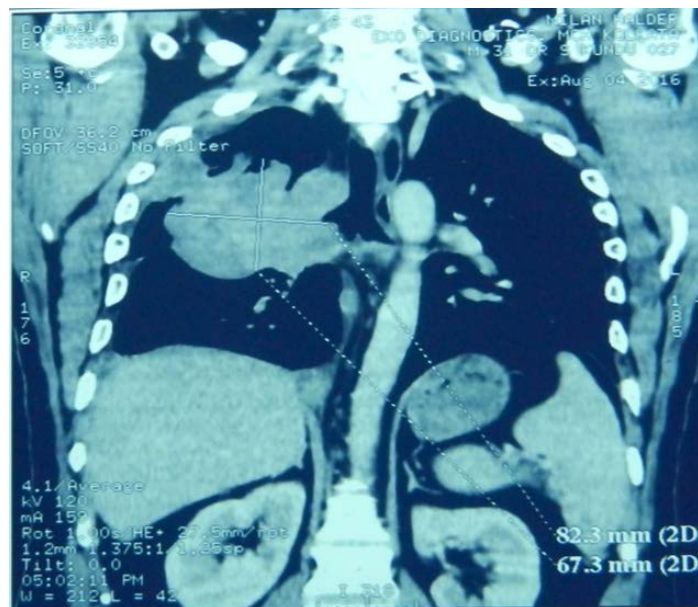


Figure 1b. CT of the chest (Coronal view)

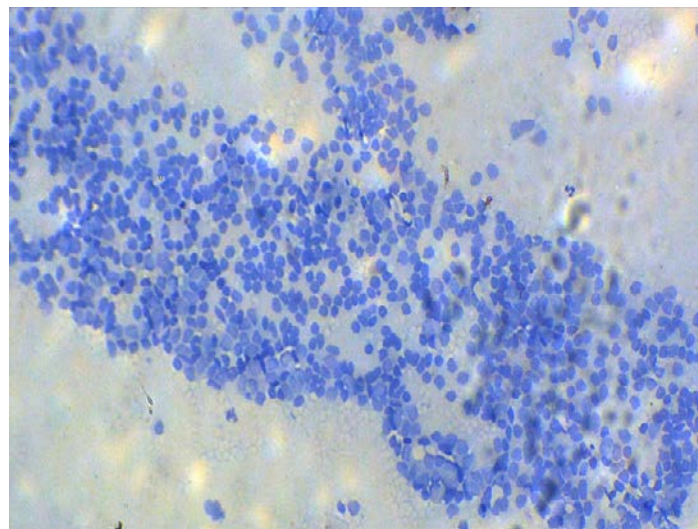


Figure 2. Fine Needle Aspiration Cytology: Low power view (10x10), H&E stain– discrete and poorly cohesive small blue round cells with irregular nuclei with coarse chromatin and scanty cytoplasm  
CT guided fine needle aspiration from the SOL revealed cytological picture of small blue round cell tumour with differential diagnosis of small cell lung carcinoma and non-Hodgkin lymphoma. Then CT guided core needle biopsy was done from the mass



and it shows lung tissue infiltrated by round or ovoid cells with hyperchromatic nuclei and scanty cytoplasm, suggestive of malignant round cell tumour.

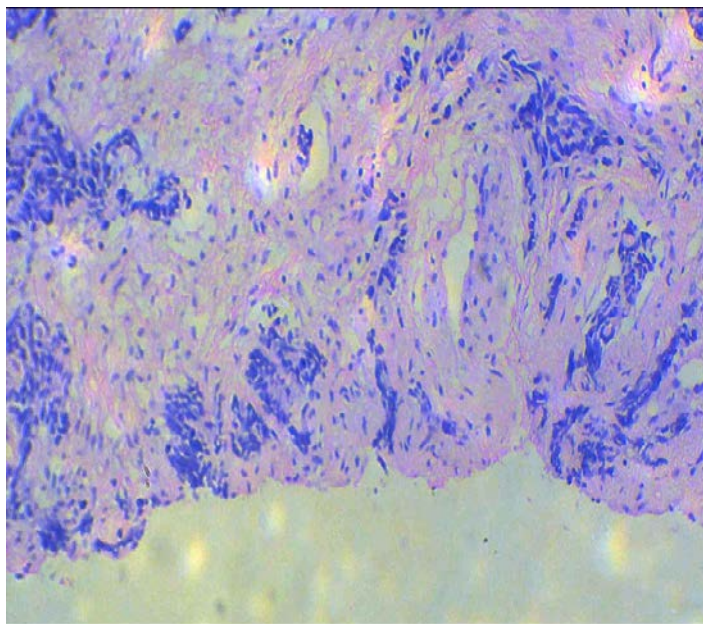


Figure 3. CT guided trucut biopsy from lung lesion: Scanner view (5x10), H&E stain – shows fibrocollagenous lung tissue infiltrated by small, blue, round or ovoid cells.

Immunohistochemistry was done to establish the diagnosis. It reveals the cells positive for FLI1, CD 56 (focal) and negative for Chromogranin, Desmin, S100, EMA, TTF1, Calretinin. The Ki-67 labelling index is about 95%. In addition, the glycoprotein p30/32 (CD99), which is encoded by the MIC2 gene, is strongly expressed on the surface of the tumor cells.[5][6]. The overall picture is compatible with PNET/ Ewing's sarcoma. Metastatic workup was done with whole body PET-CT. PET CT scan suggests metabolically active large irregular soft tissue mass in right lung upper and midzone with infiltration to adjacent pleura, multiple active metastatic pleural nodules and masses in right pleura.

There is also active metastatic lymphadenopathy in right hilar, multiple mediastinal lymph nodes.

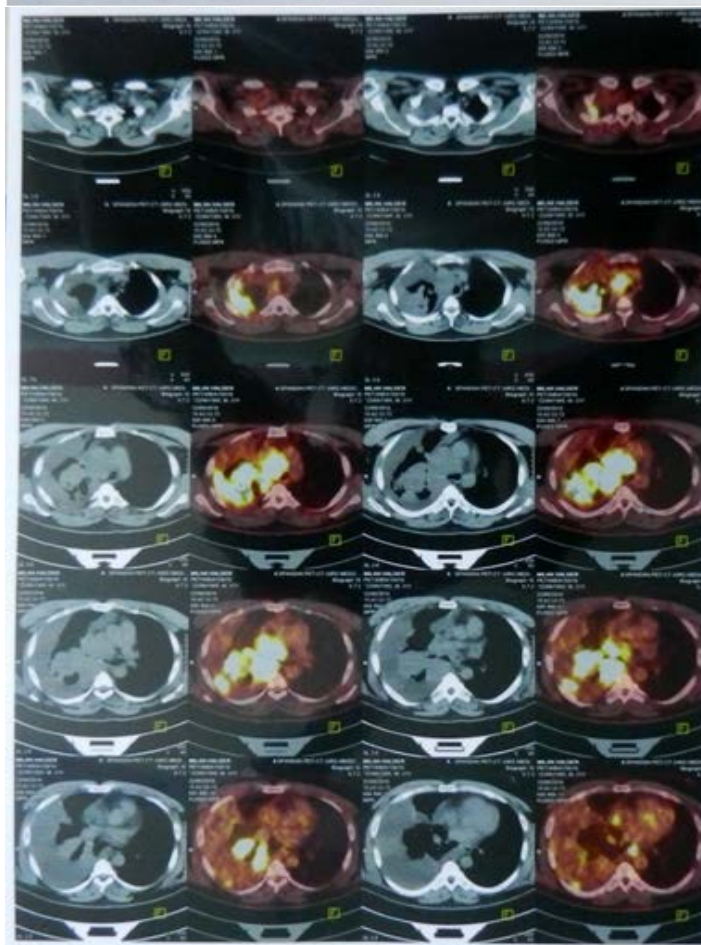
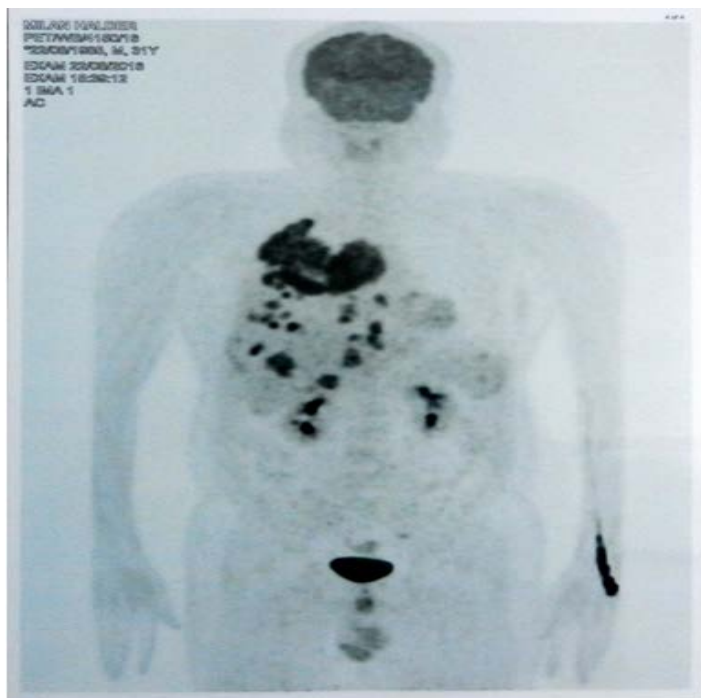

Figure 4 (a) and (b). PET-CT scan showing metabolically active large irregular soft tissue mass in upper and mid zone of right lung with ipsilateral pleural deposits and ipsilateral hilar and mediastinal lymphadenopathy.

With diagnosis of Ewing's sarcoma, VAC (Vincristine, Adriamycin, Cyclophosphamide) alternating with IE (Ifosfamide, Etoposide) chemotherapy regimen was started.

Alternating VAC/IE chemotherapy regimen

Day 1: Vincristine 2mg/m<sup>2</sup> (max 2mg) i.v. + Doxorubicin 75mg/m<sup>2</sup> i.v. + Cyclophosphamide 1200mg/m<sup>2</sup> i.v.; Dactinomycin 1.25mg/m<sup>2</sup> i.v. given substituted for Doxorubicin when total Doxorubicin dose of 375mg/m<sup>2</sup> is reached.

Day 1-5: Ifosfamide 1800mg/m<sup>2</sup> i.v. + Mesna + Etoposide 100mg/m<sup>2</sup> i.v. Repeated 3 weekly alternately for 17 cycles.

Patient after completing 17 cycles of chemotherapy, showed clinical and radiological partial response. Patient was sent to cardiothoracic department for surgical opinion. Patient underwent surgical resection and radiotherapy and now doing well at 2 months follow-up.

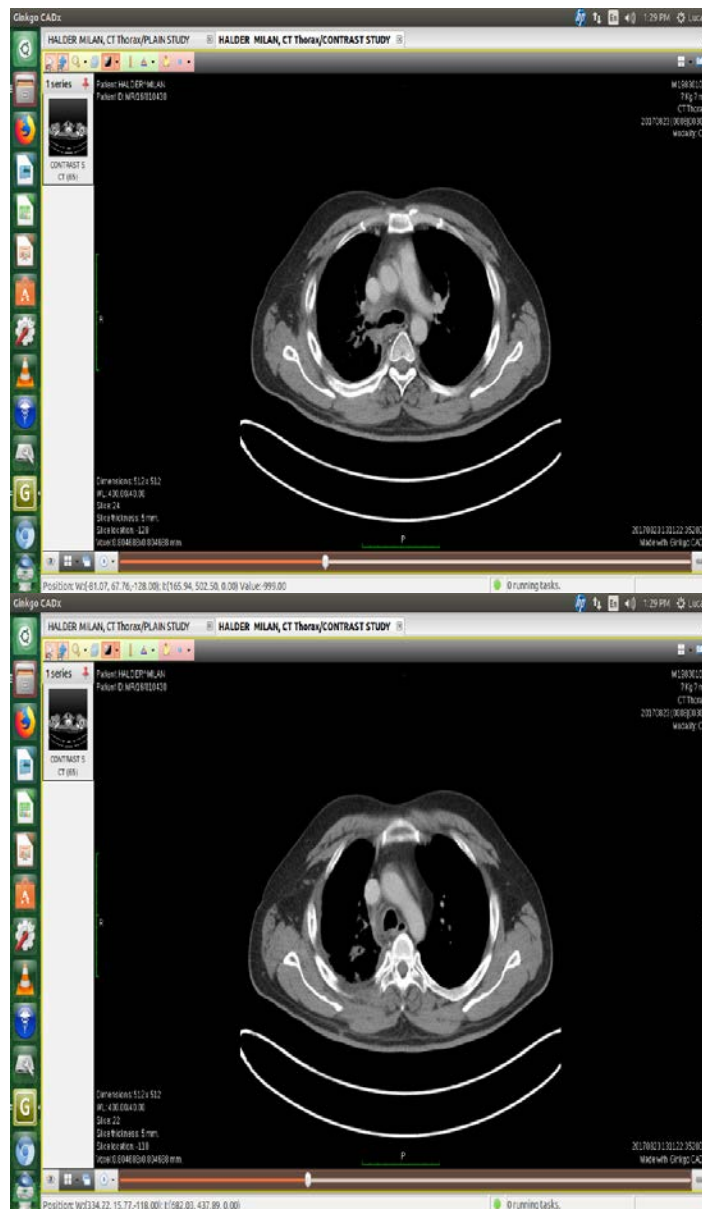

Figure 5.(a) (b) CT Scan thorax showing radiological response

#### Discussion

Ewing's sarcoma was first described in 1921 by Ewing as an undifferentiated small round cell tumour occurring in long bones of children. Ewing's sarcoma and Primitive neuroectodermal tumours are clinically and histologically identical tumours. Modern genetic study showed that both of them share a common chromosomal translocation as t(11;22)(q24;q12)[EWS-FLI1]. Hence they were

classified into the same category of ESFTs (Ewing's Sarcoma Family of Tumors) by the World Health Organization Classification in 2002. The ESFT is an uncommon malignant neoplasm. The family shares a common histological feature of closely packed small primitive round cells. ESFT most frequently arise in the bones followed by the soft tissue, but they have also rarely been reported at other sites, such as the ovaries, uterus, kidney, pancreas, colon, hard palate and lung (7–18). ESFTs may affect people of all ages and occur most often in adolescents or young adults, with slight male preponderance. However, primary PNET of the lung is an extremely rare tumour in adults.

Differential diagnoses include other round cell tumours, such as lymphoma, rhabdomyosarcoma, and neuroblastoma. Extraskelatal Ewing's sarcoma, however rare, is a diagnosis to be considered when looking at lung lesions. Diagnostic staging at presentation is paramount to identify an occult primary lesion or any early metastasis. Due to the aggressive nature of these tumours we would recommend whole body imaging. Tumour identification is critical between these tumours as treatment modalities vary. Definitive diagnosis is reached by biopsy and histological evaluation and immunohistochemistry. Confirmation of diagnosis is done by demonstration of EWS-FLI1 fusion transcript which is very much specific for Ewing's sarcoma.

There is no established definite guideline to treat Ewing's sarcoma of lung due to rarity of it. Review

of case reports indicates employment of surgery and chemotherapy with or without radiotherapy.

It can be concluded from the cases currently on record ESFT of the lung is an aggressive malignant tumour. The most significant prognostic factor in ESFT is considered to be whether the disease has spread. At diagnosis of ESFT is recognised as a systemic disease<sup>[19]</sup> and therefore, indications for systemic treatment are predictable<sup>[20]</sup>. Optimal treatment modalities remain an area of debate. Current knowledge would favour early surgical resection with additional chemotherapy<sup>[21,22]</sup>. Radiotherapy also has a role in Ewing's sarcoma as it is radiosensitive. In our case, the mass was initially unresectable. Hence we employed neoadjuvant chemotherapy regimen (i.e. VAC alternating with IE) as in case of skeletal Ewing's sarcoma. After neoadjuvant chemotherapy surgical resection and/or radiotherapy must be considered which was done in our case. No dramatic differences have been noted in treatment modalities of these lesions during the last three decades, so this remains an area for continued development where optimum treatment needs to be established.

#### References

1. Price CH, Jeffree GM. Incidence of bone sarcoma in SW England, 1946–74, in relation to age, sex, tumour site and histology. *Br J Cancer* 1977;36:511–22.
2. Grier HE. The Ewing family of tumors. Ewing's sarcoma and primitive neuroectodermal tumors. *Pediatric Clinics of North America*. 1997;44(4):991-1004. [PubMed]



3. Tefft M, Vawter GF, Mitus A. Paravertebral "roundcell" tumors in children. *Radiology* 1969;92(7):1501-9. [PubMed]
4. Suarez Antelo J, Rodriguez Garcia C, Montero Martinez C, Vereza Hernando H. [Pulmonary Ewing sarcoma/primitive neuroectodermal tumor: a case report and a review of the literature]. *Arch Bronconeumol*. 2010;46(1):44-6. Epub 2009/08/07. doi: 10.1016/j.arbres.2009.03.008 S0300-2896(09)00249- X [pii]. [PubMed]
5. Ambros IM, Ambros PF, Strehl S, Kovar H, Gadner H, Salzer-Kuntschik M. MIC2 is a specific marker for Ewing's sarcoma and peripheral primitive neuroectodermal tumors. Evidence for a common histogenesis of Ewing's sarcoma and peripheral primitive neuroectodermal tumors from MIC2 expression and specific chromosome aberration. *Cancer* 1991;67:1886-93.
6. d'Amore ES, Ninfo V. Soft tissue small round cell tumors: morphological parameters. *Semin Diagn Pathol* 1996;13:184-203.
7. Kawauchi S, Fukuda T, Miyamoto S, Yoshioka J, Shirahama S, Saito T, et al. Peripheral primitive neuroectodermal tumor of the ovary confirmed by CD99 immunostaining, karyotypic analysis, and RT-PCR for EWS/FLI-1 chimeric mRNA. *Am J Surg Pathol* 1998;22:1417-22.
8. Ng SB, Sirrampalam K, Chuah KL. Primitive neuroectodermal tumours of the uterus: a case report with cytological correlation and review of the literature. *Pathology* 2002;34:455-61.
9. Kuroda M, Urano M, Abe M, Mizoguchi Y, Horibe Y, Murakami M, et al. Primary primitive neuroectodermal tumor of the kidney. *Pathol Int* 2000;50:967-72.
10. Danner DB, Hruban RH, Pitt HA, Hayashi R, Griffin CA, Perlman EJ. Primitive neuroectodermal tumor arising in the pancreas. *Mod Pathol* 1994;7:200-4.
11. Kuwabara K, Ishida H, Shirakawa K, Yokoyama M, Nakada H, Hayashi Y, et al. Primitive neuroectodermal tumor arising in the colon: report of a case. *Surg Today* 2006;36:193-7.
12. Kang MS, Yoon HK, Choi JB, Eum JW. Extraskelatal Ewing's sarcoma of the hard palate. *J Korean Med Sci* 2005;20:687-90.
13. Hammar S, Bockus D, Remington F, Cooper L. The unusual spectrum of neuroendocrine lung neoplasms. *Ultrastruct Pathol* 1989;13:515-60.
14. Catalan RL, Murphy T. Primary primitive neuroectodermal tumor of the lung. *AJR Am J Roentgenol* 1997;169:1201-2.
15. Tsuji S, Hisaoka M, Morimitsu Y, Hashimoto H, Jimi A, Watanabe J, et al. Peripheral primitive neuroectodermal tumour of the lung: report of two cases. *Histopathology* 1998;33:369-74.
16. Imamura F, Funakoshi T, Nakamura S, Mano M, Kodama K, Horai T. Primary primitive neuroectodermal tumor of the lung: report of two cases. *Lung Cancer* 2000;27:55-60.
17. Kahn AG, Avagnina A, Nazar J, Elsner B. Primitive neuroectodermal tumor of the lung. *Arch Pathol Lab Med* 2001;125:397-9.

18. Mikami Y, Nakajima M, Hashimoto H, Irei I, Matsushima T, Kawabata S, et al. Primary pulmonary primitive neuroectodermal tumor (PNET). A case report. *Pathol Res Pract* 2001;197:113–9; discussion 121–2.
19. Zagar TM. Extraosseous Ewing's sarcoma: 25 years later. *J Clin Oncol* 2008;26:4230–4232.
20. Bernstein M, Kovar H, Paulussen M, Randall RL, Schuck A, Teot LA, Juergens H. Ewing's sarcoma family of tumors: current management. *Oncologist* 2006;11:503–519; doi: 10.1634/theoncologist. 11-5-503.
21. Takahashi D, Nagayama J, Nagatoshi Y, Inagaki J, Nishiyama K, Yokoyama R, Moriyasu Y, Okada K, Okamura J. Primary Ewing's sarcoma family tumors of the lung – a case report and review of the literature. *Jpn J Clin Oncol* 2007;37:874–877; doi: 10.1093/jjco/hym108.
22. Ahmad R, Mayol BR, Davis M, Rougraff BT. Extraskelatal Ewing's sarcoma. *Cancer* 1999;85:725–731.