

## Clinicopathological Study of Lower Gastrointestinal Tract Lesions in Per Rectal Bleeding Cases

Shivani H. Ingale<sup>1</sup>, Nanda J. Patil<sup>2</sup>

<sup>1</sup>PG student, Department of Pathology, Krishna Institute of Medical Sciences, Karad.

<sup>2</sup>Professor, Department of Pathology, Krishna Institute of Medical Sciences, Karad.

**Correspondence Author:** Shivani H. Ingale, PG student, Department of Pathology, Krishna Institute of Medical Sciences, Karad, India

**Type of Publication:** Original Research Paper

**Conflicts of Interest:** Nil

### Abstract

**Background:** Rectal bleeding occurs in 20% of population in India. Rectal bleeding is mainly a manifestation of lower gastrointestinal tract lesions, which means bleeding from a site distal to ligament of Treitz, including anal canal. Though it is a common symptom in the general population, the definitive diagnosis can not be arrived on clinical and radiological basis. Clinicopathological study plays an important role in the early diagnosis and proper management of cases of colonic lesions.

**Aim and Objectives:** To study the histopathology of various lower gastrointestinal tract lesions in patients presenting with per rectal bleeding.

To categorize different lower gastrointestinal tract lesions leading to per rectal bleeding and assess their proportions into Nonneoplastic and Neoplastic.

To correlate the clinicopathological findings with age, sex, site of lesion, radiological & endoscopic findings.

**Materials and methods:** A cross sectional prospective study on the histopathology of lower gastrointestinal tract lesions in 40 patients of per rectal bleeding was carried out in the department of pathology over 2 years (June 2015 to May 2017).

**Results:** Total 40 lesions of lower gastrointestinal tract were studied. Commonest age group involved was 41-60

years with male preponderance. Neoplastic lesions accounted for majority amongst which predominant lesions were malignant that is adenocarcinoma. Moderately differentiated adenocarcinoma involving rectum were preponderant. Majority of adenocarcinomas were in stage C1 of Astler-Coller staging. Haemorrhoids were the most common nonneoplastic lesion.

**Conclusion:** Malignant lesion is the commonest cause of per rectal bleeding amongst lower gastrointestinal tract lesions.

**Key words:** Per rectal bleeding, lower gastrointestinal tract, histopathology.

### Introduction

Rectal bleeding occurs in 20% of population in India.<sup>1</sup> Rectal bleeding is mainly a manifestation of lower gastrointestinal tract lesions, which means bleeding from a site distal to ligament of Treitz, including anal canal.<sup>2</sup> Though it is a common symptom in the general population, the definitive diagnosis can not be arrived on clinical and radiological basis. The clinicopathological study plays an important role in the early diagnosis and proper management of cases of colonic lesions. The lower gastrointestinal tract lesions presenting as per rectal bleeding includes: Hemorrhoids, Fissure in ano, Rectal prolapse, Diverticular disease, Solitary rectal ulcer syndrome, Ulcerative colitis, Colorectal polyps,

Colorectal carcinoma. <sup>3</sup>All these lesions often require biopsies for their conclusive diagnosis. Hence, a clinicopathological study plays an important role in the proper management of cases of lower gastrointestinal tract lesions. The present study includes clinicopathological correlation of 40 cases of lower gastrointestinal tract lesions presenting as per rectal bleeding.

### Materials and Methods

Present clinicopathological study of lower gastrointestinal tract lesions in patients presenting with per rectal bleeding was a prospective with 2 years duration from June 2015 to May 2017 and included total 40 cases. The study included surgical specimens of all lesions from lower gastrointestinal tract in the form of excision or resection from patients of all age groups and both sex presenting with per rectal bleeding. Patients with all kind of bleeding disorders were excluded from the study. Ethical clearance was carried out from the ethical committee of this university. Clinical data of the patients in the form of age, sex, associated complaints with per rectal bleeding, complete blood count, endoscopic findings and radiologic impressions if any were obtained from the patient hospital case sheets available directly from the wards or from the medical record section. Resected specimens were grossed according to the standard protocol. <sup>4,5</sup>The slides were stained with Haematoxylin and Eosin (H & E). Special stains such as ZN (Ziehl-Neelsen) and Mucicarmine were done wherever required. The lesions were diagnosed in the light of microscopic features, clinical details and relevant investigations.

### Results and Discussion

The study included surgical specimens of 40 cases from the lesions of lower gastrointestinal tract in the form of excision or resection.

### Age and sex distribution of cases

Of the total 40 cases, most of the lesions that is 15 cases (37.5%) were observed in the age group 41 to 60 years followed by 14 cases (35%) in the age group more than 60 years. Mean age at presentation was 56.37 years. Male to female ratio was observed as 1.85:1.

Our findings of age group & sex were in concordance with other studies. <sup>6,7,8</sup>

### Associated symptoms along with per rectal bleeding

The most common associated symptom with per rectal bleeding observed was constipation in 28 cases (70.0%) followed by weakness in 11 cases (27.5%), weight loss and pain in abdomen in 10 cases each (25.0%), mass protruding out from anal canal in 6 cases (15.0%).

Our finding was in concordance to studies done by Shefali.H.Karve et al., and Ritesh Sulegaon et al. <sup>9,10</sup>

### Investigations

Histopathological features of lower gastrointestinal tract lesions in patients presenting with per rectal bleeding were analysed according to haematological and radiological investigations. Out of total 40 cases of lower gastrointestinal tract lesions causing per rectal bleeding, 14 cases were found to have anaemia (35%). Moderate anaemia was found in 12 cases (86%) which were adenocarcinoma (6 cases), haemorrhoids (3 cases), mucinous carcinoma (2 cases) & neuroendocrine carcinoma (1 case). Mild anemia was found in 2 cases (14%) each of tubulovillous adenoma and mucinous carcinoma (7% each). Radiological investigation done were scopy (55.5%), computed tomography scan (27.7%), magnetic resonance imaging (8.3%), ultrasonography (5.5%) and barium enema (2.7%). In all 36 lesions (31 malignant lesions, 3 benign lesions and 1 case each of tuberculosis and Meckel's diverticulum) clinicopathological findings were matching with radiological imaging findings.

**Nature of lesions**

Majority of these lesions were neoplastic (34cases-85.0%) while nonneoplastic lesions were found in 6 cases (15.0%). (Table 1)Our finding was in concordance to studies done by Manthini et al and RiteshSulegaon et al. 7,10

Table1. Overall nature of lesions

Nature of lesion		Number of cases	Total number of cases	Percentage of cases	
Nonneoplastic	Haemorrhoids	4	6	15	
	Tuberculosis	1			
	Meckel's diverticulum	1			
Neoplastic	Benign	Adenoma	2	34	85
		Juvenile polyps	1		
		Adenocarcinoma	24		
	Malignant	Mucinous carcinoma	4		
		Cloacogenic carcinoma	1		
		Neuroendocrine carcinoma	1		
		Squamous cell carcinoma	1		
		Total	40		

**Site of malignant lesions**

In the present study, site wise distribution of malignant lesions was studied. Out of 31 malignant cases, majority that is 17 cases (55%) had lesions involving rectum followed by sigmoid in 12 cases (39%) and anal canal in 2 cases (6%). An ulceroproliferative pattern of growth was found in majority that is 15 cases (48%) followed by ulceroinfiltrative growth pattern in 9 cases (29%). (Fig. 1,2),).

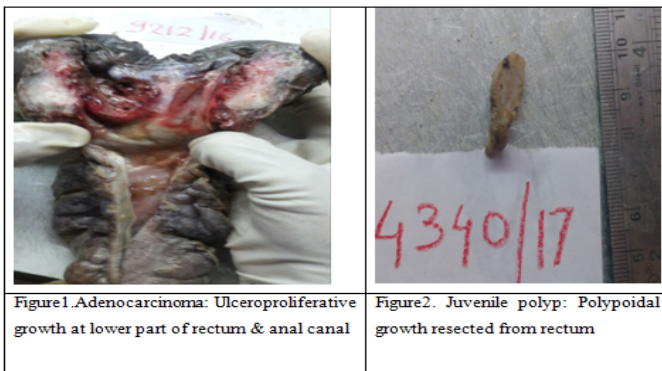


Figure1. Adenocarcinoma: Ulceroproliferative growth at lower part of rectum & anal canal  
 Figure2. Juvenile polyp: Polypoidal growth resected from rectum

Our findings were in concordance with a study done by Shah N et al. and a Nigeria based study by Umana et al. 6,8

**Distribution of nonneoplastic lesions**

Haemorrhoids were found to be the most common nonneoplastic lesions (4 cases-66%) followed by tuberculosis and Meckel's diverticulum (1 case each-17%).(figure3, 4)

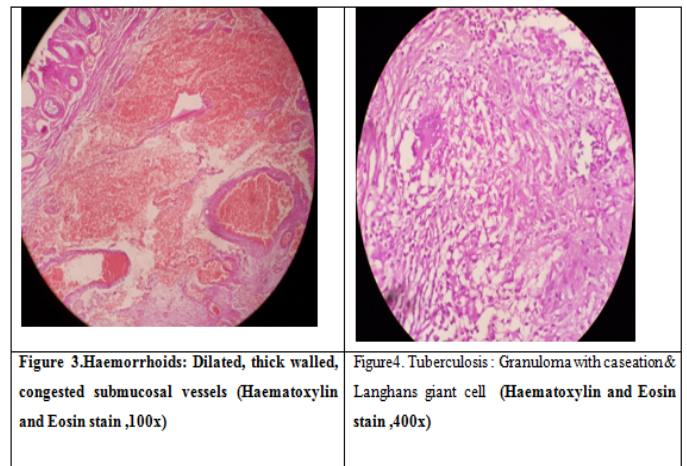


Figure 3. Haemorrhoids: Dilated, thick walled, congested submucosal vessels (Haematoxylin and Eosin stain ,100x)  
 Figure4. Tuberculosis : Granuloma with caseation & Langhans giant cell (Haematoxylin and Eosin stain ,400x)

Our finding was in concordance with other studies. 11,12

**Neoplastic lesions**

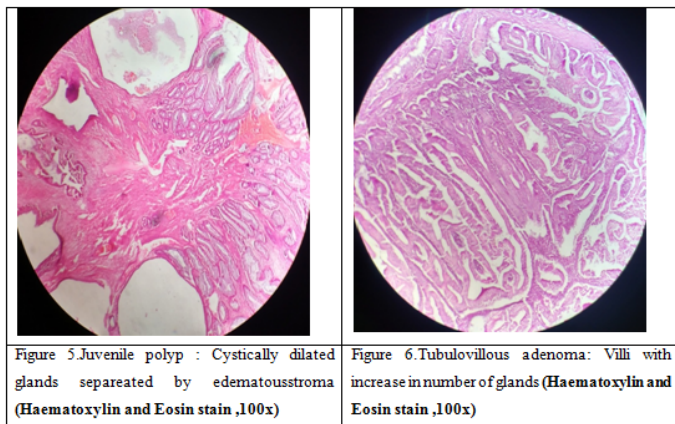
Amongst 34 neoplastic lesions, 31 cases ( 91%) were malignant lesions followed by 3 cases (9%) of benign lesions. Most of the benign lesions of lower gastrointestinal tract were observed in females (66.66%) with mean age of 33 years and most of the malignant lesions of lower gastrointestinal tract were observed in males (61.29%) with mean age of 61.48 years. Minimum age at presentation in malignant lesions was 18 years and oldest patient was of 82 years old.

Our findings were in concordance with studies done by Manthini et al and RiteshSulegaon et al. 7,10

**Benign lesions of lower gastrointestinal tract**

Out of total 34 neoplastic lesions, 3 cases (8.82%) were benign and included one case each of juvenile polyp, villous adenoma and tubulovillous adenoma. (Figure

5,6).



Thus adenomas were most common benign lesion of lower gastrointestinal tract causing per rectal bleeding

Our findings were in concordance with studies done by Manthini et al., and Tony et al.<sup>7,13</sup>

**Malignant lesions**

Out of 34 neoplastic lesions of lower gastrointestinal tract, majority that is 31 cases (91%) were malignant lesions and included 24 cases of adenocarcinoma (77.5%), 4 cases of mucinous carcinoma (12.9%), 1 case each of cloacogenic carcinoma (3.2%). Amongst the cases of adenocarcinomas, majority were moderately differentiated adenocarcinoma (18 cases-75%), followed by well differentiated adenocarcinomas (4 cases-17%) and poorly differentiated adenocarcinoma (2cases-8%). The most common symptom in these patients was per rectal bleeding associated with constipation. The most common site involved was rectum. Lymph node metastase was seen in cases of moderately differentiated adenocarcinomas (27.7%) and poorly differentiated adenocarcinoma (100%).

Our findings were in concordance with other studies.<sup>7,8,10,14</sup>

**Table 2. Staging of AC according to Astler-Coller staging system**

Astler-Coller stage	Number of cases	Percentage
A	1	3
B1	3	10
B2	10	32
C1	14	45
C2	3	10
Total	31	100

In the present study, majority of adenocarcinomas were in stage C1 that is 14 cases (45%) followed by stage B2 that is 10 cases (32%).

Alidzanovic et al. (2012) in their study found a profound number of cases in stage C2.<sup>15</sup> Our study showed maximum number of patients in the stage C1. This variation in staging of the patients could be due to early detection of tumour as the present institute being a tertiary care center.

**Cloacogenic Carcinoma**

Cloacogenic carcinoma was diagnosed in 1 case of 67 years old male patient presented with per rectal bleeding along with a mass protruding out of anal canal and pain in abdomen. Proctoscopic examination revealed a growth involving both rectum and anal canal. Subsequently patient underwent resection and specimen was sent for histopathological examination. Lymph nodes were free from tumour. (Figure 7)

**Neuroendocrine Carcinoma**

Neuroendocrine carcinoma was diagnosed in a 59 year old male patient with chief complaint of per rectal bleeding along with constipation and pain at left iliac fossa. Sigmoidoscopy revealed an ulceroproliferative growth involving sigmoid.

Patient underwent resection. Diagnosis of neuroendocrine carcinoma large cell type was given. Tumour was showing lymph node metastasis. (Figure 8)

## Squamous Cell Carcinoma

One case was diagnosed as squamous cell carcinoma in a 82 year male patient involving anal canal with metastases to perianal lymph nodes.

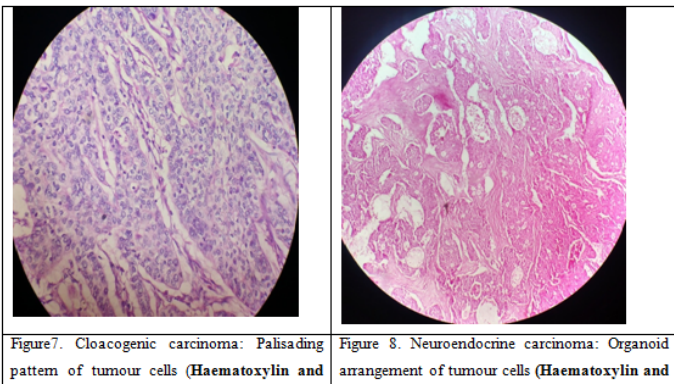


Figure 7. Cloacogenic carcinoma: Palisading pattern of tumour cells (Haematoxylin and

Figure 8. Neuroendocrine carcinoma: Organoid arrangement of tumour cells (Haematoxylin and

## Conclusions

The lesions of lower gastrointestinal tract causing per rectal bleeding are seen more commonly in male patients commonest age group being 41 -60 years.

Constipation is the commonest associated symptom in these cases.

Neoplastic lesion is the commonest cause of per rectal bleeding amongst lower gastrointestinal tract. Haemorrhoid is the frequent cause of per rectal bleeding amongst nonneoplastic lesions.

Adenoma and juvenile polyp form the majority of benign lesions of lower gastrointestinal tract causing per rectal bleeding.

Amongst neoplastic lesions, malignant lesions form the major cause of per rectal bleeding. Most of these are adenocarcinomas involving rectum and sigmoid colon.

Overall male preponderance is observed in these cases.

Adenocarcinoma of rectum and sigmoid colon is the commonest cause of per rectal bleeding leading to anaemia in cases of lower gastrointestinal tract lesions.

## References

1. Lewis JD, Brown A, Localio AR, Schwartz JS. Initial evaluation of rectal bleeding in young persons: a cost-

effectiveness analysis. *Ann Intern Med.* 2002;136(2):99-110.

2. Zuccaro G. Management of the adult patient with acute lower gastrointestinal bleeding. *The Am J Gastroenterol.*1998;93(8):1202-8.

3. Manzoor A, Shah SA, Inam A. Etiologic spectrum of bleeding per Rectum in surgical outpatient department of a tertiary care hospital. *Ann Pak Inst Med Sci.* 2011;7(4):180-5.

4. Juan Rosai, Guidelines for handling of most common and important surgical specimens. In;Rosai and Ackerman's *Surgical Pathology.*10<sup>th</sup>ed. Elsevier.2011. 2606-7.

5. Robb E. Wilentz. The digestive system. In; *Surgical Pathology Dissection: An Illustrated Guide,* 2<sup>nd</sup>ed Springer.2003;66-73.

6. Shah N, Jaisar N, Patel N, Shah CK. Histomorphological evaluation of colon lesions. *Int J Reas in Med Sci.* 2017;5(10):4254-8.

7. Manthini P, Kalahasti R, Yarlagadda SB, Devi SP, Basa A, Vaddadi M, Malyala PK. histopathological Study of Lesions of Colon.. *Int J Sci Stud.*2017;5(2):65-8.

8. Umana IO, Obaseki DE, Ekanem VJ. The clinicopathological features of lower gastrointestinal tract endoscopic biopsies in Benin City, Nigeria. *Saudi J.Surg* 2017;5(1):2-9.

9. Karve SH, Vidya K, Shivarudrappa AS, Prakash CJ. The Spectrum of colonic lesions: A Clinico-pathological study of colonic biopsies. *IndJ PatholOncol.* 2015;2(4):189-209.

10. Sulegaon R, Shete S, Kulkarni D. Histological Spectrum of Large Intestinal Lesions with Clinicopathological Correlation. *J ClinDiagn Res.* 2015;9(11):EC30.

11. Nikpour S, Asgari AA. Colonoscopic evaluation of minimal rectal bleeding in average-risk patients for

- colorectal cancer. *World J Gastroenterol.* 2008;14(42):6536.
12. Manzoor A, Shah SA, Inam A. Etiologic spectrum of bleeding per Rectum in surgical outpatient department of a tertiary care hospital. *Ann Pak Inst Med Sci.* 2011;7(4):180-5.
13. Tony J, Harish K, Ramachandran TM, Sunilkumar K, Thomas V. Profile of colonic polyps in a southern Indian population. *Ind J Gastroenterol.* 2007;26(3):127-33.
14. Caliskan C, Guler N, Karaca C, Makay O, Firat O, Korkut MA. Negative prognostic factors in colorectal carcinoma: An analysis of 448 patients. *Ind J Surg.* 2010;72(3):243-8.
15. Alidžanović J, Pavlović N, Salkić N, Zerem E, Čičkušić A. Epidemiological, clinical and pathological characteristics of colorectal cancer in patients treated at the Clinical Center of Tuzla University. *Med Glas.* 2012;9(1):29-35.