

Histopathological study of Appendix: A Study In Consecutive 1000 appendectomiesDr.Anuradha¹, Dr.Vanita kumar ², Dr.Shree Rathore³, Dr.Neelu Gupta⁴¹Resident, Department of Pathology, S.P.medical College, Bikaner, Rajasthan²Professor, Department of Pathology, S.P.medical College, Bikaner, Rajasthan³Student, Dr. MPK Homeopathic Medical College, Jaipur, Rajasthan⁴Professor, Department of Pathology, S.P.medical College, Bikaner, Rajasthan**Correspondence Author:** Dr.Anuradha, Resident, Department of Pathology, S.P.medical College, Bikaner, Rajasthan**Type of Publication:** Original Research Paper**Conflicts of Interest:** Nil**Abstract**

Introduction-Appendicitis is a very common surgical emergency and has a lifetime risk of 7%.It is approximately 1.4 times greater in men than in women. Misdiagnosis and delay in surgery can lead to complications like perforation and finally peritonitis. Appendiceal tumors are unusual accounting for 0.4% of all gastrointestinal tract malignancies. An estimated 1% of all appendectomy specimens contain a neoplasm. The majority of appendicular tumors are carcinoids while the remaining 10-20% are mucinous cyst adenocarcinoma, adenocarcinoma, lymphoma, paraganglioma and granular cell tumor.

Objectives of Study

1. To study the patterns of lesions (non-neoplastic and neoplastic) in the appendectomy specimens.
2. To study the detailed morphological features of the different non- neoplastic and neoplastic lesions i.e. both benign and malignant.
3. To correlate the clinical diagnosis with the histopathological diagnosis of the appendectomy specimens.

Materials and Methods: This was a prospective and retrospective study from January 2015 to December 2017

in the department of pathology, S.P. Medical College, Bikaner, Rajasthan.

Results

A total of 1000 appendectomies were received during the period of January 2015 to December 2017. Acute appendicitis was the most common pathology (including all form of acute) reported (45.6%). Next common lesion was Healing appendicitis with peri-appendicitis (32.8%) followed by Healed appendicitis (15.7%) followed by chronic appendicitis (3.6%) followed by tubercular appendicitis(0.5%) then mucocele was 0.3% and adenocarcinoma was also 0.3% followed by parasite(*E.vermicularis*) 0.2% then 0.1% was Carcinoid was reported.

The age of patient ranged from 15 days to 80years with mean age 23.32years.Male to female ratio was 2.23: 1

Conclusion: So, we concluded that the histopathological spectrum of appendix after appendectomy is extremely variable. Appendix is one of the organs having a wide spectrum of diseases ranging from congenital anomalies, inflammatory to neoplastic lesions.. We recommend all appendectomy specimens should be submitted to histopathology laboratory, as appendix cancer can be detected at an early, potentially curable stage, only by histopathological examination.

Keywords: acute appendicitis, Adenocarcinoma, Chronic appendicitis, E.vermicularis

Introduction

Appendicitis is a very common surgical emergency and has a lifetime risk of 7%.It is approximately 1.4 times greater in men than in women¹. Misdiagnosis and delay in surgery can lead to complications like perforation and finally peritonitis. Therefore certain scoring systems like Alvarado Scoring System are established which aid in the diagnosis of acute appendicitis, provides high degree of positive predictive value and thus diagnostic accuracy².

Appendiceal tumors are unusual accounting for 0.4% of all gastrointestinal tract malignancies. An estimated 1% of all appendectomy specimens contain a neoplasm. The majority of appendicular tumors are carcinoids while the remaining 10-20% are mucinous cyst adenocarcinoma, adenocarcinoma, lymphoma, paraganglioma and granular cell tumor³. Not only has the pathologic diagnosis of acute inflammation, at times unusual findings such as incidental tumors highlighted the importance of pathologic analyses of every single resected appendix.

Materials and Methods

This was a prospective and retrospective study from January 2015 to December 2017 in the department of pathology, S.P.Medical College, Bikaner,Rajasthan.

Appendectomy specimens received were fixed in 10% neutral buffered formalin and embedded in paraffin .Three sections were obtained from tip,mid part and base of appendix. Additional sections were taken from any grossly abnormal area if present. Sections were then stained with H&E stain and examined microscopically.

Results

A total of 1000 appendectomies were received during the period of January 2015 to December 2017. Acute appendicitis was the most common pathology (including all form of acute) reported (45.6%).Acute appendicitis

with peri-appendicitis was the most common pathology reported (39.1%) in all form of acute appendicitis, Next common lesion was Healing appendicitis with peri-appendicitis (32.8%) followed by Healed appendicitis (15.7%) followed by chronic appendicitis (3.6%) followed by tubercular appendicitis(0.5%) then mucocele was 0.3% and adenocarcinoma was also 0.3% followed by parasite(E.vermicularis) 0.2% then 0.1% was Carcinoid was reported.(Table 1)

The age of patient ranged from 15 days to 80years with mean age 23.32 years (Table2).Male to female ratio was 2.23: 1(Table2).

Table1-Leisons of Appendix among appendicectomies

Code	Histopathological Diagnosis	Sex				Total	
		Female		Male			
		No.	%	No.	%	No.	%
A	Acute appendicitis (including of all forms of acute appendicitis)	112	11.2	344	34.4	456	45.6
B	Acute appendicitis (Acute appendicitis with periappendicitis)	88	8.8	303	30.3	391	39.1
C	Acute appendicitis going towards healing	03	0.3	07	0.7	10	1
D	Acute appendicitis with granulomatous reaction	01	0.1	00	0	01	0.1
E	Acute appendicitis with perforation	03	0.3	00	0	03	0.3
F	Acute necrotizing appendicitis (including Acute necrotizing appendicitis with periappendicitis)	05	0.5	14	1.4	19	1.9
G	Acute on chronic appendicitis	02	0.2	04	0.4	06	0.6
H	Acute Suppurative appendicitis (with peri-appendicitis)	10	1	16	1.6	26	2.6
I	Chronic appendicitis	14	1.4	22	2.2	36	3.6
J	Tubercular appendicitis	03	0.3	02	0.2	05	0.5
K	Gangrenous appendicitis	00	0	01	0.1	01	0.1
L	Healedappendicitis(with peri-appendicitis)	64	6.4	93	9.3	157	15.7
M	Healing appendicitis(with peri-appendicitis)	108	10.8	220	22.0	328	32.8
N	Hemorrhagic appendicitis	01	0.1	00	0	01	0.1
O	Parasite (E.Vermicularis)	01	0.1	01	0.1	02	0.2
P	Adenocarcinoma	01	0.1	02	0.2	03	0.3
Q	Carcinoid	00	0	01	0.1	01	0.1
R	Mucocele	00	0	03	0.3	03	0.3
S	Normal appendix	06	0.6	01	0.1	07	0.7
T	Total	310	31	690	69	1000	100

Table 2- Distribution of cases according to age group(Year)

Age group	No.of cases	%
<_ 20	489	48.9
21-30	257	25.7
31-40	127	12.7
41-50	69	6.9
51-60	32	3.2
61-70	18	1.8
>70	8	0.8
Total	1000	100
Mean Age (years)	23.32(Years)	

Table 3- Distribution of cases according to Sex

Sex	No. of Cases	%
Female	309	30.9
Male	691	69.1
Total	1000	100

Table 4-Histopathological diagnosis of appendix carcinoma found in this study

1	Histopathological diagnosis	Sex				Total	
		Female		Male		N	%
		No.	%	N	%		
2	Adenocarcinoma	1	0.1	2	0.2	3	0.3
3	Carcinoid	0	0	1	0.1	1	0.1

Among 4 cases of malignancy, adenocarcinoma was found in 3 cases and 1 case of carcinoid reported.

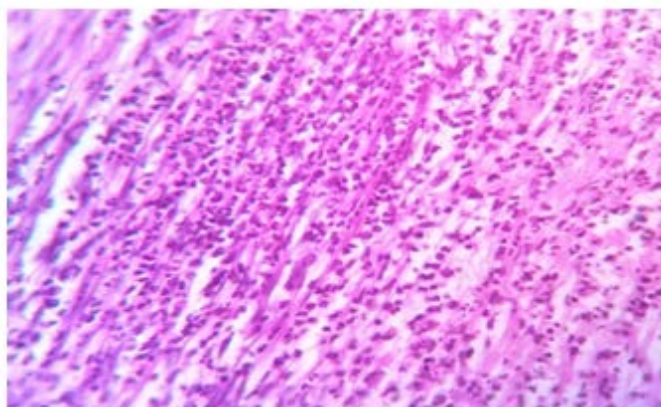


Figure1:Acute appendicitis. (H&E,40X) showing dense infiltrate of neutrophils .

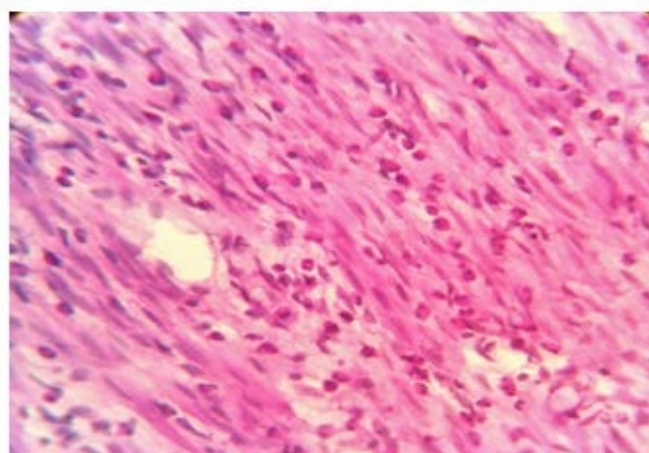


Figure2: Healing appendicitis(Acute eosinophilic appendicitis) (H&E,40X).

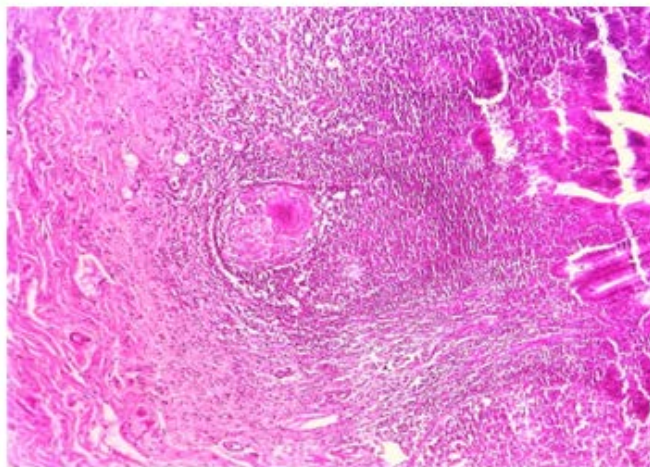


Figure3. TB OF APPENDIX (10X H&E) SHOWING GRANULOMA FORMATION

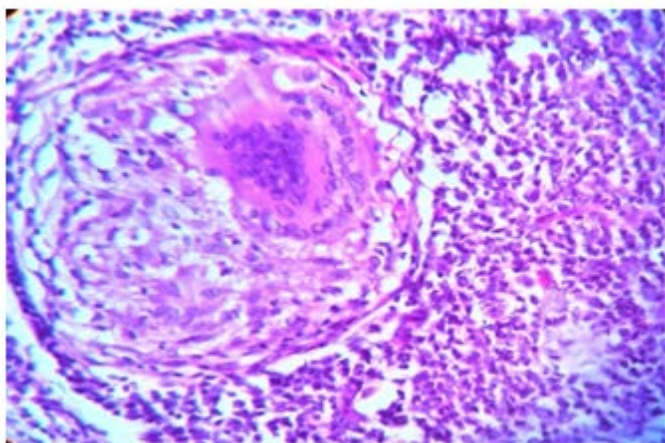


Figure 4 -Tb of Appendix 40x Showing giant cell, Epithelioid Cells & Fibroblastic Reaction

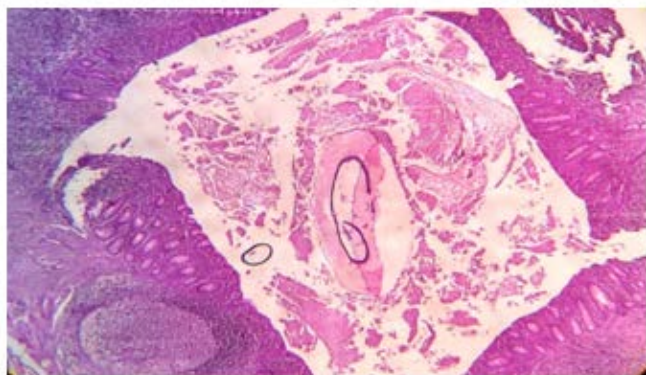


Figure 5: H&E (40X) SHOWING E.VERMICULARIS IN LUMEN OF APPENDIX

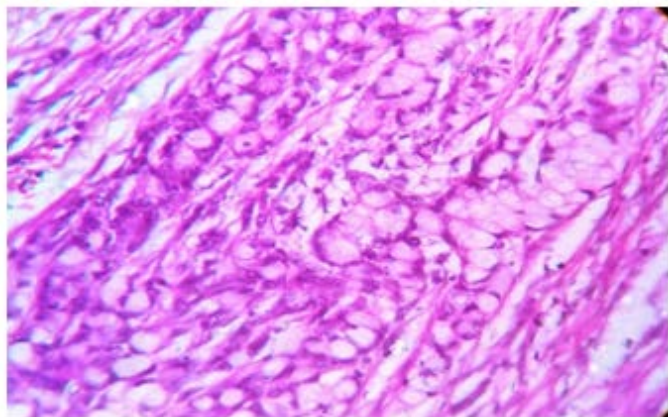


Figure 6: ADENOCARCINOMA OF APPENDIX 40X H&E

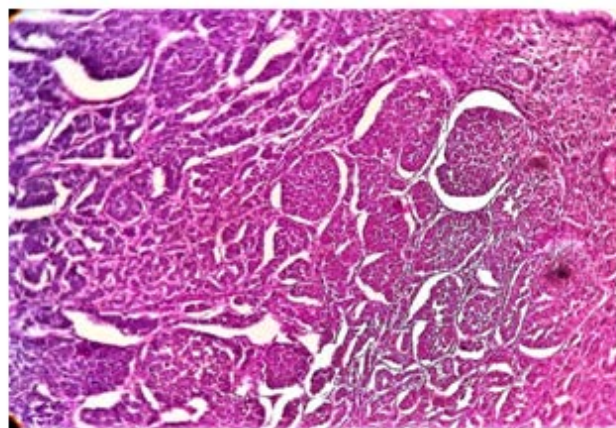


FIGURE 7 -CARCINOID OF APPENDIX (10X)

Discussion

The histopathological spectrum of appendix disease after appendectomy is found to be quite diverse. The incidence of appendix lesion varies depending upon on races, countries, and institutes. The present study was carried on 1000 appendectomy specimen to study various histopathological lesions in resected appendix.

In present study, lesions of appendix were more common in males than in females with a male to female ratio of 2.23:1 which was similar to other study carried out by Hakan Yabanoğlu et al⁴, Hanish Kumar Chawda et al⁵, Dhiraj B. Nikumbh et al⁶ and Dr Bharti Devi Thaker et al⁷ reported male to female ratio of 1.63:1, 1.56:1, 2.34:1 and 2.7:1 respectively.

In our study, the age of the patients ranged from 15 days to 80 yrs with mean age 23.32 yrs which is similar with study of Nadir Mehmood et al⁸ in which mean age was 23 yrs. In study of Dr Bharti Devi Thaker et al⁷ mean age was 34 yrs and in study of K. H. in't Hof et al⁹ mean age was 32.7 yrs. Most of the patients were <20 yrs (48.9%), followed by age group 21-30 years (25.7%).

Most of the patients presented with pain abdomen, nausea/vomiting and few were asymptomatic, which is consistent with findings by Rajesh Patil, Narain V.N. et al¹⁰.

Dr. Mohsin-ul-Rasool et al¹¹, Suhailur Rehman et al¹² reported that majority of lesions of appendix were non-neoplastic lesions (98-99%) and neoplastic lesions were (0.6-1.5%). Dr. Medha P. Kulkarni et al¹³ reported 99.34% were involved by non-neoplastic lesions and 0.66 % by neoplastic lesions. Dr Bharti Devi Thaker et al⁷ reported that 99% were non neoplastic lesions and 1% was neoplastic. The present study is comparable to the above studies (non-neoplastic lesion was 99.6% and 0.4 % was neoplastic lesion).

In present study, out of total 1000 patients, Acute appendicitis was the most common pathology (including all form of acute) reported (45.6%). They were characterized by neutrophilic infiltration with frequent ulcer formation, gangrenous changes and abscess formations. Acute appendicitis with peri-appendicitis was the most common pathology reported (39.1%) in all form of acute appendicitis, then Acute suppurative appendicitis with peri-appendicitis (2.6%), then Acute necrotizing appendicitis (1.9%), followed by acute appendicitis going towards healing (1%) followed by acute on chronic appendicitis (0.6%), acute appendicitis with perforation (0.3%), acute appendicitis with granulomatous reaction (0.1%). A similar study was done by Mohammad Ayub Jat et al¹⁴ also reported acute appendicitis as major histopathological finding, identified in 52% cases. Hanish Kumar Chawda et al⁵ reported as acute appendicitis most common finding (57.32%). Dr Bharti Devi Thaker et al⁷ reported most common histopathological spectrum was Acute appendicitis (65.4%). Suhailur Rehman et al¹² reported 192 (60.8%) cases of acute appendicitis.

Next common lesion was Healing appendicitis with peri-appendicitis (32.8%)%. Out of which 108 were female and 220 were males. The mean age was 25.26 yrs. Aravindan K. P. et al¹⁵ found incidence of healing appendicitis was

6.25% and Dhiraj B. Nikumbh et al⁶ found 6.8% incidence of healing appendicitis.

The incidence of Healed appendicitis was (15.7%)%, out of which 64 were female and 93 were males, the mean age of healed appendicitis was 25.57 yrs followed by chronic appendicitis found in 36 (3.6%) cases. Mohammad Ayub Jat et al¹⁴ done study in which 12 cases (out of 480) of chronic appendicitis found and incidence was 2.5%. Suhailur Rehman et al¹² reported 7.9% incidence of chronic appendicitis.

The incidence of tubercular appendicitis in our study is 0.5%. There were 3 females and 2 males found with tubercular appendicitis in our study. The mean age was 20.8 yrs. Similar study done by Chong V H et al¹⁶ in which incidence was 0.08%. and Nadir Mehmood et al⁸ reported 1.8% incidence of tubercular appendix.

In our study the incidence of appendicitis with parasite (*E. vermicularis*) was 0.2%. Out of which 1 was female and 1 was male. The mean age was 24 yrs. Results are comparable with studies done by Özgür Aydın et al¹⁷ & Arif Emre et al¹⁸ in which parasite found in 3.15% and 0.6% respectively.

Mucocele of appendix was found 0.3%. All were males. Mean age of the patients was 31.66 yrs as comparable with study done by Rajesh Patil, Narain V.N. et al¹⁰ in which 1.47% patients were diagnosed to have mucocele of the appendix on histopathologic examination. Average age of presentation was 53 yrs.

In present study incidence of adenocarcinoma was 0.3%. Out of which one female and 2 males. Mean age of the patients was 40 yrs and M:F ratio was 2:1. Results are comparable with study done by Suhailur Rehman et al¹² in which 0.3% cases of adenocarcinoma found.

In our study 0.1% cases of carcinoid reported while study done by Suhailur Rehman et al¹² reported 0.6% cases of carcinoid.

References

1. Craig S. Appendicitis acute. Acta Paediatr.,2001; 90(6):649-651.
2. Khan I, Rehmen AU; Application of Alvarado scoring system in diagnosis of acute appendicitis. J Ayub Med Coll Abbottabad.,2005; 17(3): 41-44.
3. Mahteme H, Sugarbaker PH; Br J Surg., 2004;91(9):1168-1173
4. Hakan Yabanoğlu, Huseyin Ozgur Aytac, Emin Turk, Erdal Karagulle, Kenan Çalışkan, Sedat Belli, Fazilet Kayaselcuk, Mehmet Akın Tarım: Parasitic Infections of the Appendix as a Cause of Appendectomy in Adult Patients. Department of General Surgery, Başkent University Faculty of Medicine, Ankara, Turkey Department of Pathology, Başkent University Faculty of Medicine, Ankara, Turkey. urkiye Parazitol Derg 2014; 38: 12-6
5. Hanish Kumar Chawda , Arun T. Miskin , V.D. Dombale. Spectrum of histopathological lesion in surgically removed appendix: Journal of Drug Discovery and Therapeutics: Volume 3, Issue 28, May, 2015, 53-56
6. Dhiraj B. Nikumbh, Rajesh Y. Thakur, Sudhir Singhavi and Shirish Gondane: Histopathological Analysis of Unusual Findings in Appendectomy Specimens: A Retrospective Study and Literature Review: Annals of Pathology and Laboratory Medicine, Vol. 03, No. 03, July - September 2016.
7. Dr Bharti Devi Thaker, Dr Deepti Gupta, Dr Kailash Singh: Histopathology of Appendectomy Specimen: A 5 Year Hospital Based Study: JMSCR Volume 05 Issue 06 June 2017.
8. Nadir Mehmood¹, Huma Mushtaq² and Saeed Alam³ Histopathological Analysis of Cases Presenting with Acute Appendicitis: Journal of Islamabad Medical & Dental College (JIMDC); 2014;3(1):11-14
9. K. H. in 't Hof & H. C. van der Wal & G. Kazemier & J. F. Lange: Carcinoid Tumour of the Appendix: An Analysis of 1,485 Consecutive Emergency Appendectomies. J Gastrointest Surg (2008) 12:1436–1438
10. Rajesh Patil , Narain V.N. , Veerendra Patil , Soumya Patil: Mucocele of the Appendix : A five years Retrospective Study: J Pub Health Med Res 2013;1(2):66-70.
11. Mohsin-ul-Rasool, Shaveta Sharma, Deepti Mahajan, Shazia Bashir, Ather Hafiz, Mir Wajahat: Histopathology of Appendectomy Specimen: A 5 Year Study Scholars Journal of Applied Medical Sciences (SJAMS) Sch. J. App. Med. Sci., 2014; 2(1B):176-180.
12. Rehman S, Khan AI, Ansari HA, Alam F, Vasenwala SM, Alam K, et al. Retrospective analysis of appendectomy specimens: A tertiary care center-based study. Saudi Surg J 2017;5:71-5.
13. Dr. Medha P. Kulkarni, Dr. (Mrs.) Kalpana Ranjitsingh Sulhyan, Dr. Shaikhali M. Barodawala, Dr. Deepika Hanumanprasad Yadav: Histopathological Study of Lesions of the Appendix: International Journal of Health Sciences & Research
14. Jat MA, Al-Swailmi FK, Mehmood Y, Alrowaili M, Alanazi S. Histopathological examination of appendectomy specimens at a district hospital of Saudi Arabia. Pak J Med Sci 2015;31(4):891-894.
15. Aravindan K. P., Deepthy Vijayaraghavan, Marie Therese Manipadam: Acute eosinophilic appendicitis and the significance of eosinophil - Edema lesion: Indian journal of pathology and microbiology - 53 (2), april - june 2010.
16. Chong V H, Telisinghe P U, Yapp S K S, Chong C F: Tuberculous appendix: a review of clinical

presentations and outcomes: Singapore Med J 2011;
52(2): 90-93.

17. Özgür Aydın: Incidental parasitic infestations in surgically removed appendices: a retrospective analysis: Diagnostic Pathology 2007, 2:16.

18. Arif Emre, Sami Akbulut, Zehra Bozdog, Mehmet Yilmaz, Murat Kanlioç, Rabia Emre, Nurhan Sahin: Routine Histopathologic Examination of Appendectomy Specimens: Retrospective Analysis of 1255 Patients: Int Surg 2013;98:354–362.