

Occult Type II Dents in Dente Revealed By Cone Beam Computed Tomography in a Rare Case of Ekman Westborg Julin Syndrome

¹Kayalvizhi EB, MDS Senior lecturer Department of Oral Medicine and Radiology, Madha Dental College & Hospital, Kundrathur, Chennai, India.

²John Balaih, MDS, Senior lecturer, Department of Oral Medicine and Radiology, Indira Gandhi Institute of Dental Sciences, Pondicherry, India.

³David Livingstone, MDS, Reader, Department of Prosthodontics, Indira Gandhi Institute of Dental Sciences, Pondicherry, India.

⁴Thirumurugan K, M.D.S, Assistant Professor, Department of Oral Maxillo Facial Surgery, Mahatma Gandhi Post Graduate Institute Of Dental Science, Pondicherry

Correspondence Author: Kayalvizhi EB, MDS, Senior lecturer Department of Oral Medicine and Radiology, Madha Dental College & Hospital, Kundrathur Chennai. India.

Conflicts of Interest: Nil

Abstract

Ekman Westborg Julin Syndrome is rare syndrome with very few cases reported in the literature. Multituberculism, dens in dente, single rooted maxillary molars, macrodontia, and anterior open bite are features of this syndrome. A 23 year old male patient reported to the clinic with the chief complaint of irregularly aligned maxillary anterior teeth affecting aesthetics. Family history revealed no parental consanguinity. Based on the clinical features of multitubercles, macrodontia, maxillary labial high frenal attachment, transposition of bilateral maxillary canine, two supernumerary incisors, a syndrome was suspected. Intraoral periapical radiograph of supernumerary teeth was nondiagnostic due to superimposition of permanent maxillary central incisors. Panoramic radiograph showed single rooted maxillary molars, a feature of Ekman Westborg Julin Syndrome. Cone beam computed tomography of extracted supernumerary tooth revealed Type II Dens in Dente in two separate supernumerary teeth, which incidentally was also a feature of Ekman WestborgJulin Syndrome.

Keywords: Cone beam computed tomography, dens in dente, Ekman Westborg Julin Syndrome.

Introduction

Macrodontia has been reported to be associated with a large number of syndromes such as the Ekman WestborgJulin Syndrome, otodontal syndrome, 47 XYY syndrome, facial hemi hyperplasia and insulin resistant diabetes.

Isolated cases of bilateral supernumerary teeth were present with unusual morphology. Both the supernumerary teeth had multiple tubercles with developmental grooves have also been reported as a rare anomaly.

Depending on their size and morphology of the tooth structure a variety of functional and esthetic problems that may require surgical, and/or orthodontic treatment. Our aim is to present the new case report which appears clinical sings and radiographic findings of Ekman Westborg Julin trait and also represents the unique features were present, namely transposition of bilateral maxillary canine and bilateral type II Dens in Dente in two

separate supernumerary teeth. CBCT was done to show the complete obliteration of pulp chamber by the invagination, with separate pulp cavities

Case Report

A 23 year old male patient reported to the clinic with a complaint of misaligned maxillary anterior teeth affecting aesthetics. The patient appeared healthy with normal physical development for his age and was not mentally challenged. The medical history was non contributory. Family history revealed no parental consanguinity. Intraoral examination revealed severe maxillary anterior teeth crowding, peak shaped cuspids and anterior open bite. Palatal to maxillary central incisors, two giant supernumerary teeth were present with unusual morphology. Both the supernumerary teeth had multiple tubercles with developmental grooves (Figure 1). They were supraerupted resulting in anterior open bite. Patient also had generalized enamel hypoplasia involving the cervical area. Based on the clinical presentation of bilateral supernumerary teeth with Angle's class I malocclusion producing severe maxillary anterior teeth crowding and open bite, a syndrome was suspected.

In intraoral periapical radiographs, due to superimposition of maxillary anterior teeth over supernumerary teeth, the demarcation between enamel, dentin, pulpal structures, and periradicular structures were not clearly defined and hence did not help in diagnosis. Panoramic radiograph revealed no other pathology. Interestingly, important hints to diagnose Ekman Westborg Julin syndrome was present in the panoramic radiograph namely single conical root in maxillary molars, and enlarged mandibular third molar with multiple tubercles (Figure 2). Cone beam computed tomography (CBCT) was chosen to solve the enigmatic internal morphology of both supernumerary teeth. However, considering radiation exposures to the patient and as both supernumerary teeth were planned for

extraction as a part of orthodontic treatment, CBCT was made for both extracted supernumerary teeth. CBCT revealed the cross sectional, sagittal, and axial view of teeth showing complete obliteration of pulp chamber by the invagination, with separate pulp cavities (Figure 3). The invagination crossed the cemento-enamel junction and extended into the root which corresponds to type II Dens in Dente. It also revealed deep developmental groove directly communicating with the pulp cavity and making it more susceptible to early development of pulpal and periapical pathologies.

Ground section of the supernumerary teeth also confirmed a clear enamel lined invagination into the pulp chamber with thinning and lateral displacement of pulp. Incidentally, Dens in Dente is a feature of Ekman Westborg Julin syndrome. This particular case is unique as two more new findings were present, namely transposition of bilateral maxillary canine and bilateral type II Dens in Dente in two separate supernumerary teeth. Complex odontome has been described as an additional feature of Ekman Westborg Julin syndrome.⁽¹⁾

Discussion

Ekman Westborg Julin Syndrome or trait is rare conditions with males are more commonly affected than females in the ratio of 5:2.⁽²⁾ It is also referred as multiple macrodontic multituberculism.⁽³⁾ The features of Ekman Westborg Julin Syndrome are generalized macrodontia, multituberculism, anterior openbite, single rooted maxillary molars, dens invaginatus, and shoveling of incisors. Only one case reported in the literature showed autosomal dominant pattern of inheritance while the others did not show any pattern of inheritance. No family histories of parental consanguinity or occurrence in sibling were reported in the literature.⁽⁴⁾ Genetic studies need to be done in the future to solve the genetic mystery of Ekman Westborg Julin Syndrome.

Multiple macrodontia is associated with insulin resistant diabetes, otodontal syndrome, or facial hemi hyperplasia. (5,6,7,8,9) Generalized macrodontia is also seen with pituitary gigantism. In 47, XYY syndrome, generalized macrodontia and shovel shaped incisors have been reported. (10,11) Large maxillary incisor was reported in KBG syndrome.

The enamel lining is often deficient at the base of the invagination. (12) This case presented with true macrodontia and had deficient enamel lining. The generalized macrodontia resulted in serious orthodontic anomalies such as anterior open bite and crowding. Multituberculism and invagination increase dental caries susceptibility. Also it is easier for pulpal infections to develop owing to the morphological abnormality. Same morphological abnormality complicates endodontic treatment and in this case, extraction of both supernumerary teeth was attempted. In order to address crowding, anterior open bite, and esthetics, patient was referred for orthodontic treatment. (Figure 4)

Conclusion

Ekman julin trait is a quite rare in Indian population and developmental dental anomalies must be suspected for syndromes. Appropriate treatments must be initiated due to the early involvement of pulp in cases with dents in dente. Esthetic and functional correction is done if deemed necessary.

Conflicts of interests: None. Source of funding: None.

References:

[1]. Guvan Kayaoblu. A case of Ekman-Westborg-Julin trait: Endodontic treatment of a macrodontic incisor. *Oral Surg Oral Med Oral Pathol Oral Radiol Endod* 2009;107(5):e89-692.

[2]. Nemes JA, Alberth M. The Ekman-Westborg and Julin trait: Report of a case. *Oral Surg Oral Med Oral Pathol Oral Radiol Endod* 2006;102:659-62.

[3]. Gayle Tieszen Reardon, Rebecca L. Slayton, Clinton Norby, Teresa Geneser. Macrodonia, Shovel-shaped Incisors, and Multituberculism: Probable Ekman-Westborg-Julin Trait. *J Dent Child* 2012;79(3):197-201.

[4]. Yoda T, Ishii Y, Honma Y, Sakai E, Enomoto S. Multiple macrodonts with odontoma in a mother and son: A variant of Ekman-Westborg-Julin syndrome. *Oral Surg Oral Med Oral Pathol Oral Radiol Endod* 1998;85:301-3.

[5]. Holmes J, Tanner MS. Premature eruption and macrodontia associated with insulin resistant diabetes and pineal hyperplasia. Report of two cases. *Br Dent J* 1976;141:280-3.

[6]. Jorgenson RJ, Marsh SJ, Farrington FH. Otodontal dysplasia. *Birth Defects* 1975;11:115-9.

[7]. Van Doorne L, Wackens G, De Maeseneer M, Deron P. Otodontal syndrome. A case report. *Int J Oral Maxillofac Surg* 1998;27:121-4.

[8]. Rowe NH. Hemifacial hypertrophy. Review of the literature and addition of four cases. *Oral Surg Oral Med Oral Pathol Oral Radiol Endod* 1962;15:572-87.

[9]. Mac Millan AR, Oliver AJ, Reade PC, Marshall DR. Regional macrodontia and regional bony enlargement associated with congenital infiltrating lipomatosis of the face presenting as unilateral facial hyperplasia. Brief review and case report. *Int J Oral Maxillofac Surg* 1990;19:283-6.

[10]. Alvesalo L, Osborne RH, Kari M. The 47, XYY male, Y chromosome, and tooth size. *Am J Hum Genet* 1975;27:53-61.

[11]. Herman J, Pallister PD, Tiddy W, Opitz JM. The KBG syndrome- a syndrome of short stature, characteristic facies, mental retardation, macrodontia and skeletal anomalies. *Birth defects* 1975;11:7-1.

[12]. Judit A Nemes, Martha Alberth. The Ekman-Westborg and Julin trait: report of a case. *Oral Surg Oral Med Oral Pathol Oral Radiol Endod* 2006;102:659-62.

Legends:

Figure 1: Intraoral examination revealing severe maxillary anterior teeth crowding, and supernumerary teeth with multiple tubercles.

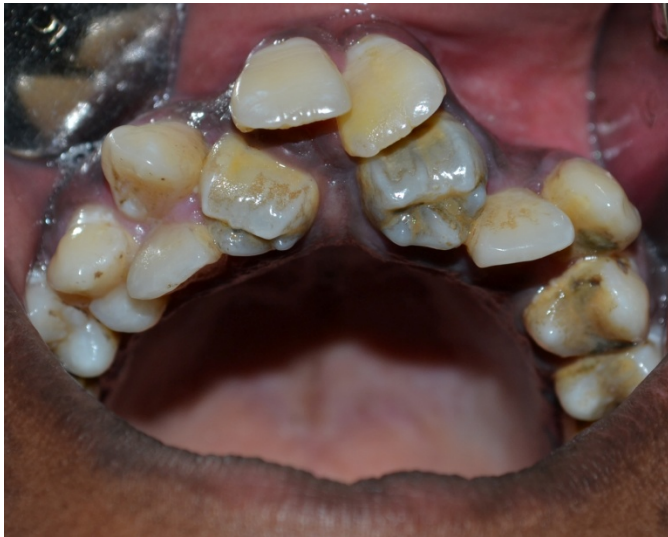

Figure 2: Panoramic radiograph showing single conical root in maxillary molars, and enlarged mandibular third molar with multiple tubercles.

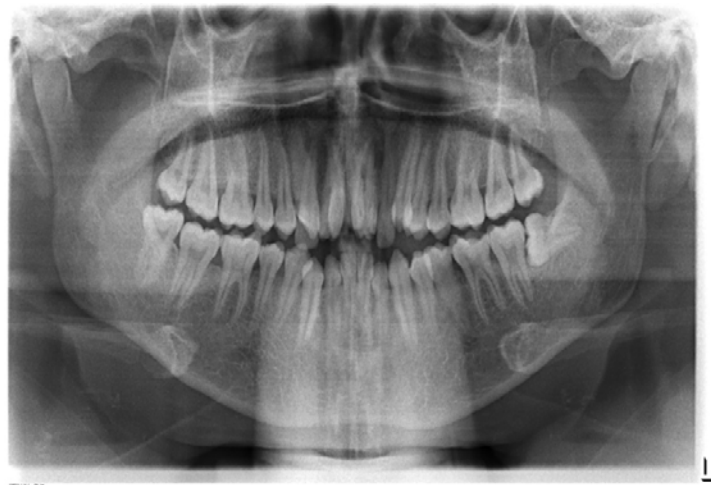

Figure 3: Cone beam computed tomography showing cross sectional, sagittal, and axial view of supernumerary teeth with complete obliteration of pulp chamber along with thinning and lateral displacement of pulp.

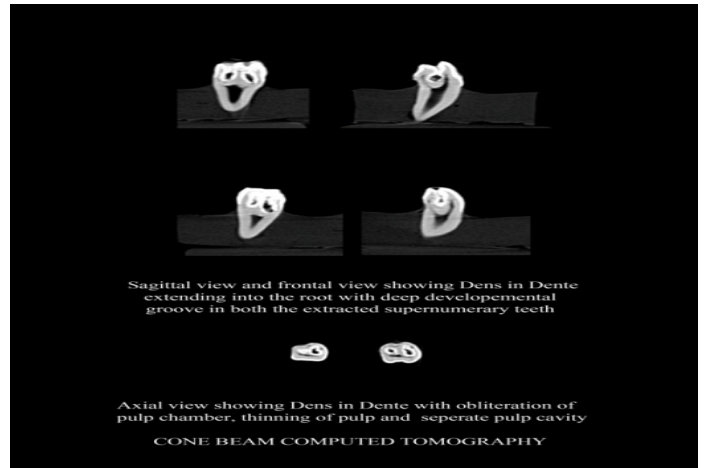


Figure 4: patient was referred to orthodontic treatment for esthetic correction.

