



## **Long Term Outcome of A Tmj Discectomy. Pseudo- Disc Formation after Silastic Implant. Case Report and Short Literature Review.**

Fabrizio Spallaccia M. D.; Francesco Paparo M. D.; Ph. D; Andrea Rivaroli M. D.; Ph. D; Mauro Massarelli M.D.; Vito Sciannameo M.D.

Azienda Ospedaliera “S.Maria” – Dipartimento Testa-Collo – Struttura Complessa di Chirurgia Maxillo- Facciale –  
Direttore f.f. Dott. Fabrizio Spallaccia– Terni - Italy

**Corresponding Author:** Francesco Paparo M. D.; Ph. D - Azienda Ospedaliera “S.Maria” di Terni – S.C. Maxillo-Facciale - Piazzale Tristano di Joannuccio - 05100 Terni – Italy; tel. And Fax. +390744205448

### **Abstract**

Temporomandibular joint disorders (TMJ) are a widespread cause of facial pain, headaches, joint noises and limited mouth opening. TMJ disc displacement is the most common disorder whereas benign tumors involving the TMJ, such as osteomas, are quite rare. Osteoma is a benign lesion that occurs in the bones of the craniofacial complex. It is a slow- growing, asymptomatic and usually solitary lesion which affects mainly young adults. Osteomas occurring in either the condyle or condylar process may result in morphologic and functional disturbances including TMJ dysfunction. Silastic is a flexible and inert silicone rubber (polydimethylsiloxane) with resilient properties, easily carved, readily adaptable to the TMJ, and it does not allow tissue ingrowth. Silastic implants can have 1 to 2 mm thickness and be reinforced with Dacron (or polyethylene terephthalate) fibers. Silastic has been used since the 1960s for joint replacements of the small bones of the hands and feet and the first reported use in the temporomandibular joint (TMJ) was in 1969. Researchers demonstrated that different forms of Silastic implants became surrounded by a fibrous capsule. It was thought that solid silicone fulfilled many of the requirements of an ideal implant material even though occasional intracellular particles of silicone elastomer were observed inside tissue macrophages. In 1981,

silicone rubber replacement after TMJ discectomy became popular. However, reports published after 1982, demonstrated long-term instability of this material in the TMJ, FBGCR around fragmented silicone particles, peri-implant lymph nodes containing silicone particles, and a severe reactive synovitis, sometimes resulting in destructive arthritis of the condyle. These implants were subsequently removed from the market in January 1993. The rationale of silicon sheets seems to be avoiding adhesions between the fossa and the condyle thus possibly improving the mechanical conditions for joint functioning. Its use has been limited to surgically treated TMJ for advanced stages of disc displacement, extensive manifestation of destructive and irreversible inflammatory disorders. Since any material which is inserted into the TMJ is subject to considerable loading, these observation seem to be of interest to evaluate the long- term behavior of alloplastic implants and its effect on clinical function. This appears to be valid either for the clinician or the researcher.

**Keyword:** TMJ, Long-term, Outcomes, Clinical Function, Tissues.

### **1. Introduction**

Temporomandibular joint disorders (TMJ) are a widespread cause of facial pain, headaches, joint noises and limited mouth opening (1;2). TMJ disc displacement

is the most common disorder whereas benign tumors, such as osteomas, are rare. Osteoma is a slow-growing, asymptomatic and usually solitary lesion affecting mainly young adults. Osteomas occurring in the condyle may result in TMJ dysfunction (3).

Silastic is a flexible and inert silicone rubber (polydimethylsiloxane) readily adaptable to the TMJ, and it does not allow tissue in growth and pseudo-arthritis. Silastic has been used since the 1960s for joint replacements of the small bones of the hands and feet and the first reported use in the temporomandibular joint (TMJ) was in 1969 (4; 5). Researchers demonstrated that different forms of Silastic implants became surrounded by a fibrous capsule (6).

It was thought that solid silicone fulfilled many of the requirements of an ideal implant material even though occasional intracellular particles of silicone elastomer were observed inside tissue macrophages (7;8). In 1981, silicone rubber replacement after TMJ discectomy became popular(9).

However, reports published after 1982, demonstrated long-term instability of this material in the TMJ sometimes resulting in destructive arthritis of the condyle. These implants were subsequently removed from the market in 1993(10; 11). Silicon sheets should avoid adhesions between the fossa and the condyle thus improving the mechanical conditions for joint functioning. Its use has been limited to extensive manifestation of destructive and irreversible inflammatory disorders of TMJ

(12). Since any material which is inserted into the TMJ is subject to considerable loading, these observation seem to be of interest to evaluate the long-term behavior of alloplastic implants and its effect on clinical function. This appears to be valid either for the clinician or the researcher.

## **2. Case Report**

A 57-Year-old woman referred to our hospital on February 2008 complaining about in gravescent limited and left-sided mouth opening and local pain in the left TMJ. A diffuse swelling and marked pain in the left pre-auricular area was observed even if skin color was normal. Maximum mouth opening was 30mm. We thus opted to perform a CT scan which documented a poorly-delineated bony mass on the superior aspect of the left mandibular condyle, like a mushroom (FIG.1). The lesion was in contact with the glenoid fossa with well delineated high density compartments of various sizes inside thus invading the superior joint space and limiting condylar movements. On March 2008, the patient underwent open joint surgery. Under general anesthesia a pre-auricular tragal incision was performed and after temporal vessels ligation and blunt dissection TMJ was exposed and opened with a vertical incision at its lateral aspect. At the superior aspect of the condyle an osseous mass involving almost all the condylar head was clearly visible. The disc was completely disrupted and the lesion contacted the glenoid fossa via the upper joint compartment with some notes of fibrous ankylosis. All pathological tissue was then isolated and removed. Thus, a condylar remodeling was performed to re-adapt the condyle itself to the fossa. Discectomy was finally performed to remove the almost completely disrupted disc. Finally a silicon sheet (Silastic) was inserted in to the joint space and fixed to the glenoid fossa with non-absorbable suture to replace the removed disc thus avoiding friction between condyle and fossa (FIG. 2) Soon after surgery non facial palsy was observed and either pain or mandibular movement improved. At week four pain was almost completely disappeared and mouth opening recovered almost completely. Definitive histology confirmed the presence of a condylar osteoma. We did not notice the

patient for more than 7 years when, on September 2015 patient came once more to our observation complaining the recent re-onset of local pain on the left TMJ. Mouth opening was slightly limited and no local swellings were observed. Due to the previous clinical history of the patient we decided to perform a CT scan which documented an apparent osteoma relapse at the medial aspect of the condyle requiring new surgical intervention (FIG. 3). On January 2016 the patient underwent second open surgery in which we completely removed the osteoma recurrence extended from the superior aspect of the condyle to the medial aspect of the condylar head at the pterygoid muscle insertion. Once removed the mass we were able to clearly observe the long-term outcome of Silastic interposition on either the fossa or the condyle itself. We unexpectedly found that there was a novel superior joint space formed by an almost complete neo-discal fibrous tissue macroscopically similar to a normal TMJ disc. Silastic sheet was in position. Moreover no migration of the implant was observed and nonabsorbable stitches used to fix the implant to the surrounding tissue were still evident (FIG. 4). Post-operative recovery was fast. No major complications were noted. At present the patient is asymptomatic.

### **3. Discussion**

Many alloplastic interpositional materials have been used in times for the surgical management of the grossly destroyed TMJ. Among these, Silicon sheets, like Silastic have been extensively employed to avoid adhesions between the fossa and the condyle and to improve joint movements. Despite its importance there are only few studies concerning the long-term effects of alloplastic materials implants. Schillephake et al, in 1996 published an extended retrospective study on 48 patients undergone alloplastic replacement of TMJ disc (4). The study concluded that alloplastic implants did not give significant

advantages in the TMJ disc reconstruction due to either histopathological findings of foreign body reactions or lack of implant fixation following joint heavy and continuous load. Moreover, fibrous adhesions, persistence of TMJ pain, limited mouth opening and inflammatory infiltrations were the most frequent clinical and histological evidences. Concerning radiographic findings, many patients suffered from considerable thinning and resorption of the condyle which was more frequent for the patients implanted by silicon. McKenna in 2001 concluded that all alloplastic implants did not give significant improvements in surgical outcome as compared with discectomy alone (12). Moreover reported a higher incidence of progressive destructive condylar lesions. Frichton et al in 2002 determined the long-term outcomes of TMJ implant surgery for the treatment of disc displacement making a cross-sectional study among 466 patients. Results showed that the group having TMJ surgery without implants had statistically better outcome (7). Despite all these findings, in which the value of interpositional material was never substantiated, in 1985, Hall HD, published a study in which was wondered that Silastic sheeting would also promote growth of connective tissue that could mature to articular cartilage and serve as a disc (13). To date there is only one paper like this published by worldwide authors. In this paper we report another case in which Silastic interposition in a disrupted TMJ, unexpectedly led to the formation of novel superior joint space formed by an almost complete neo-discal tissue looking like a normal TMJ disc. This finding seemingly is in contrast with the conclusions of many clinical studies among alloplastic interpositional materials in which are mainly observed fibrous adhesions and inflammatory infiltrations as the most frequent histological evidence (4, 5, 6, 9, 10, 11). This would be due to the continuous joint load over the implant together

with the lack of a durable fixation. Thus, no clinical advantages were noted comparing Silastic implantation in a joint undergone discectomy. Nevertheless, when we opened the joint of our patient for the second time, despite the osteoma recurrence, Silastic was very well fixed in its original position and did not appear either eroded or affected by any degenerative change. Moreover there was a novel disc and a novel superior compartment. In conclusion we believe that the observation of long-term outcome of alloplastic TMJ implants can be useful to either researchers or clinicians to be able to understand the biological behavior of these materials thus better focusing the future directions of Research.

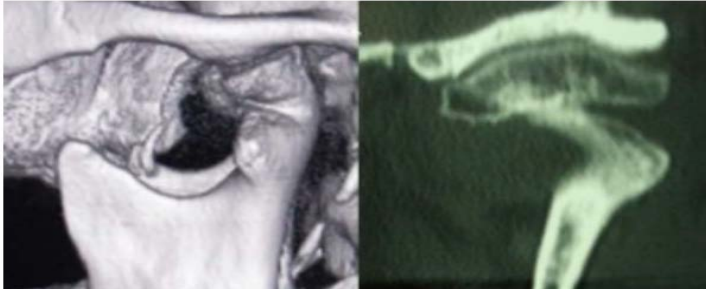#### **4. References**

1. Okeson, J. (1996). *Orofacial Pain: Guidelines for assessment, Diagnosis and Management*. Carol Stream, IL: Quintessence Publishing.
2. Dimitroulis G. Temporomandibular disorders: a clinical update. *BMJ*. 1998 Jul 18; 317(7152): 190-4.
3. do Egito Vasconcelos BC, Porto GG, Bessa-Nogueira RV. Rare benign tumors of the mandibular condyle: report of 2 cases and literature review. *J Oral Maxillofac Surg*. 2007 Sep; 65 (9): 1830-5.
4. Schliephake H, Schmelzeisen R, Maschek H, Haese M. Long-term results of the use of silicone sheets after discectomy in the temporomandibular joint: clinical, radiographic and histopathologic findings. *Int J Oral Maxillofac Surg*. 1999 Oct; 28 (5): 323-9.
5. Niamtu J 3rd, Mercuri LG. Silastic implants for temporomandibular joint disorders. *Plast Reconstr Surg*. 2001 Jan; 107 (1): 290-1.
6. Wolford LM. Temporomandibular joint devices: treatment factors and outcomes. *Oral Surg Oral Med Oral Pathol Oral Radiol Endod*. 1997 Jan; 83 (1): 143-9.
7. Friction JR, Look JO, Schiffman E, Swift J. Long-term study of temporomandibular joint surgery with alloplastic implants compared with nonimplant surgery and nonsurgical rehabilitation for painful temporomandibular joint disc displacement. *J Oral Maxillofac Surg*. 2002 Dec; 60 (12): 1400-11.
8. Eriksson L, Westesson PL. Destructive lesions of the mandibular condyle following discectomy with temporary silicone implant. *Oral Surg Oral Med Oral Pathol*. 1987 Feb; 63(2): 143-50.
9. Eriksson L, Westesson PL. Results of temporomandibular joint discectomies in Sweden 1965-85. *Swed Dent J*. 1987; 11 (1-2): 1-9.
10. Westesson PL, Eriksson L, Lindström C. Destructive lesions of the mandibular condyle following discectomy with temporary silicone implant. *Oral Surg Oral Med Oral Pathol*. 1987 Feb; 63(2): 143-50.
11. Eriksson L, Westesson PL. Deterioration of temporary silicone implant in the temporomandibular joint: a clinical and arthroscopic follow-up study. *Oral Surg Oral Med Oral Pathol*. 1986 Jul; 62(1): 2-6.
12. McKenna SJ. Discectomy for the treatment of internal derangements of the temporomandibular joint. *J Oral Maxillofac Surg*. 2001 Sep; 59(9): 1051-6.
13. Hall H: Meniscectomy for damaged disks of the temporomandibular joint. *S Med J* 78: 569, 1985.

**FIGURES and LEGEND**

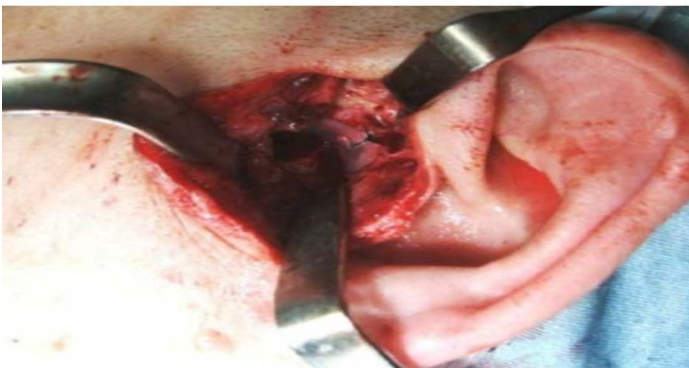**Fig. 1**

CT scan showing a poorly- delineated bony mass on the superior aspect of the mandibular condyle (first presentation).



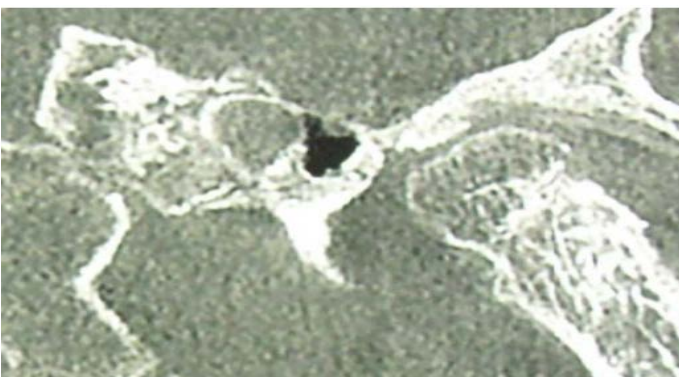
**Fig. 2**

First surgical intervention: Silastic is inserted into the joint space after condylar remodeling. It is fixed to the glenoid fossa with non- absorbable stitches.



**Fig. 3**

CT scan showing the osteoma relapses at the medial aspect of the condyle requiring new surgical intervention



**Fig. 4**

Second surgical intervention: A novel superior joint space formed by an almost complete neo-discal fibrous tissue macroscopically similar to a normal TMJ discis well visible. The Silastic sheet is still in position and non-absorbable stitches used to fix the implant to the surrounding tissue are well evident.

