

Rare Case Report - Axillary Fibroadenoma

¹Kala Sanjay, ²Singh Ujjwal Pal

¹Dr Sanjay Kala Professor and Head, Department of General Surgery GSVM Medical College Kanpur

²Dr Ujjwal Pal Singh, Junior Resident, Department of General Surgery GSVM Medical College Kanpur

Corresponding Author: Dr sanjay kala, Professor and Head, Department of General Surgery GSVM Medical College Kanpur

Type of Publication: Case Report

Conflicts of Interest: Nil

Abstract

The Common congenital anomalies of breast are polymastia (supernumerary breast) and polythelia (supernumerary nipple); always do not fail to amuse the clinician because of their variable presentations, associated urological anomalies, and pathology arising from them. The axillary polymastia is a variant of ectopic breast tissue (EBT). Ectopic breast tissue can undergo the same pathological processes as the normally located breast. The incidence of fibro adenoma rare pathology in ectopic breast, the most common pathology affecting ectopic breast being carcinomas. Case Presentation. A 31-year-old Indian female presented with a lump of 4 cm in the right axilla for the past year which gradually increased in size, giving discomfort. Our initial differential diagnosis was fibro adenoma, lipoma, and lymphadenopathy. In Country like India Tuberculous Lymphadenopathy is among the differentials. Histopathology report of excision biopsy confirmed it as a fibro adenoma on ectopic breast tissue in the axilla. Patient has no associated urological or cardiac anomaly.

Keywords: Axillary fibro adenoma, supernumerary breast, ebt, mammary line.

Introduction

Swellings in the axilla especially in women are always viewed with suspicion owing to a large number of these being associated with breast carcinomas presenting as nodal metastasis. Carcinoma is reported as the common pathology followed by inflammation and fibro adenoma. We report a case of fibro adenoma in the axilla for its rarity and to explain the importance of considering the ectopic breast and its associated pathology in the differential diagnosis of axillary mass and also the importance of evaluating the patients to rule out urological malignancies as it is an important association.

Case Presentation

A 26-year-old Indian female came presenting with the complaints of mass in the left axilla for one year which is gradually increasing in size and associated with pain.

Examination

On examination, 4 × 4.5 cm size swelling is noted in the right axilla. It is firm in consistency, tender on palpation, freely mobile, and completely separate from the right breast. Skin over the swelling is normal, with no nipple or

areola made out. Both the breast and right axilla are clinically normal. A provisional differential diagnosis of fibro adenoma, lipoma, and lymphadenopathy was made.

Investigations: Ultrasonogram of the local parts showed 3 * 4 cm mass in the right axilla with well-defined and smooth margins and homogenous, hypo echoic internal echoes with low vascularity in the lesion, characteristic of fibro adenoma. Both breasts are normal. Ultra sonogram of the abdomen showed no renal anomaly. Fine needle aspiration cytology (FNAC) report showed cluster of ductal epithelial cell admixed with darkly stained myoepithelial cells along with stromal fragment few cells are showing apocrine changes background shows hemorrhage and bipolar nuclei suggestive of strong possibility of fibro adenoma with florid hyperplasia.

Treatment

Patient underwent excision biopsy. Per operative finding was a subcutaneously located lesion which was excised. This anatomically superficial location of the lesion explains why this is an example of ectopic breast tissue rather than an extension of breast parenchyma into the axilla (axillary tail of Spence) which is located deep. Histopathological examination of the resected specimen is also suggestive of circumscribed mass comprising of glandular and stromal hyperplasia glandular hyperplasia show both pericanicular and intracanicular pattern of glandular proliferation benign proliferative disease fibro adenoma (mixed type) axillary extension of breast.

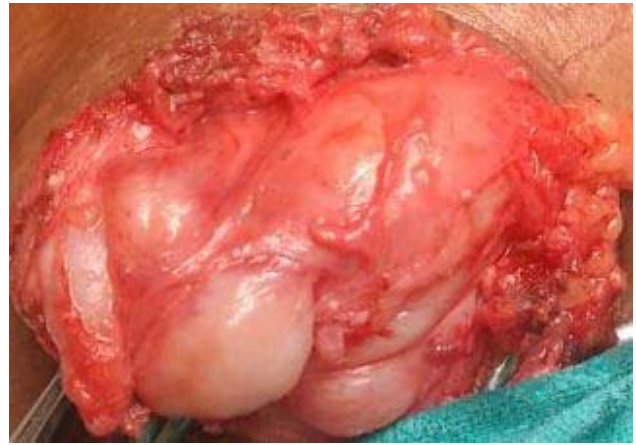

Figure.1 Surgical Exposure Of Fibroadenoma Of Accessory Breast In Axilla

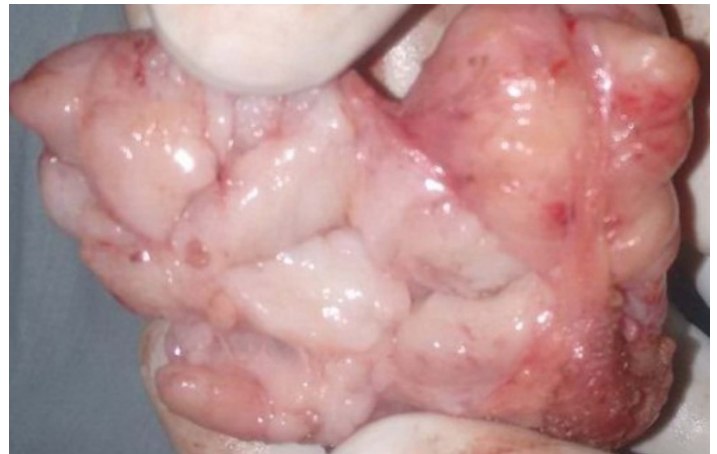

Figure.2 Excised Fibroadenoma

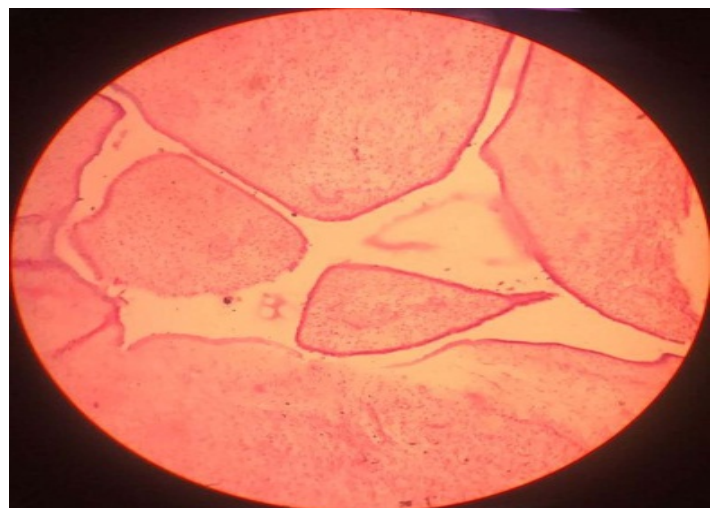


Figure 3 Histology Of Fibroadenoma

Circumscribed mass comprising of glandular and stromal hyperplasia glandular hyperplasia show both pericanicular

and intracanicular pattern of glandular proliferation benign proliferative disease fibro adenoma (mixed type) axillary extension of BREAST.

Discussion

When breast tissue (glandular component/nipple areola complex/both) occurs at sites other than two pectoral regions, it is termed as ectopic breast tissue/supernumerary breast/accessory breast. incidence of EBT is 0.4 to 6% among female and in males it is 50% of female incidence.

During the 6th week of embryonic development, the mammary milk lines, which represent 2 ectodermal thickenings, develop along the sides of the embryo, extending from the axillary region to the groin. In normal development, most of the embryologic mammary ridges resolve, except for 2 segments in the pectoral region, which later become breasts. Failure of any portion of the mammary ridge to involute can lead to ectopic breast tissue with (polythelia) or without (polymastia) a nipple-areolar complex. Therefore, ectopic breast usually occurs along the "milk line" or mammary line.

Ectopic breast tissues are reported in locations other than the milk line, face, foot, lumbar region, vulva, and perineum. Supernumerary tissues present in any location other than along the milk line are supported by two beliefs. One is that it represents a migratory arrest of breast primordium during chest wall development; the other belief is that it develops from the modified apocrine sweat glands. approximately 67% of accessory breast tissue occurs in thoracic or abdominal portions of the milk line more often on the left side and only 20% occurs in axilla.

In 1915, Kajava published a classification system for supernumerary breast tissue that remains in use today. Class I consists of a complete breast with nipple, areola,

and glandular tissue. Class II consists of nipple and glandular tissue but no areola. Class III consists of areola and glandular tissue but no nipple. Class IV consists of glandular tissue only. Class V consists of nipple and areola but no glandular tissue (pseudo mamma). Class VI consists of a nipple only (polythelia). Class VII consists of an areola only (polytheliaareolaris). Class VIII consists of a patch of hair only (polytheliapilosa). Our case belongs to class IV.

Usually ectopic breast tissue occurs sporadically, but a hereditary predisposition has also been reported. In most cases, accessory breasts are asymptomatic and cause nothing more than a visible distension which may resemble a tumor. Sometimes it could cause psychological disturbances in adolescence and it may give pain and discomfort especially during menstruation, pregnancy, and lactation. The clinical significance of the polythelia and polymastia lies in the fact that apart from the psychological and cosmetic impact, it develops the same pathological changes as the normally located breast tissue such as inflammation, fibrosis, fibro adenoma, cystosarcomaphyllodes, and carcinoma. Usually carcinoma arising from the ectopic breast presents late with poorer prognosis due to delay in the diagnosis. This delay happens due to a broad differential diagnosis for an axillary lesion, including lipoma, sebaceous cyst, vascular lesions, suppurative hidradenitis, cat scratch disease, and lymphadenopathy, secondaries in lymph nodes, tuberculosis, axillary tail of Spence, or even a torn muscle belly and malignancies.

The next important point is that these ectopic breast tissue patients, especially polythelia cases, have been associated with urinary abnormalities such as supernumerary kidneys, failure of renal formation, renal adenocarcinoma, hydronephrosis, polycystic kidney disease, duplicate renal

arteries, and ureteric stenosis. This association can be partly explained by the parallel development of mammary structure and genitourinary system. Our patient is not associated with any associated urinary abnormalities.

If EBT is associated with any suspicion, then further investigation with FNAC, ultra sonogram, mammography, and biopsy should be done as for any other breast lesion. In routine screening programmes for breast cancer, a clinical examination should be made for the presence of EBT, and, if present, that should be subjected to routine screening as well, along with the normally positioned breast.

Conclusion

In conclusion, when tumors or nodules are found along the mammary line, the presence of breast tissue should be considered during the investigation. It is clinically wise to evaluate and screen carefully cases of supernumerary breast for any pathology and for any associated urogenital anomalies. FNAC is very valuable in perioperative diagnosing the lesion in EBT. The treatment options for EBT depend upon the psychological factors, symptoms, and the presence of pathology. In our case, excision of the fibro adenoma has been done successfully with no postoperative complication and the patient is on regular follow-up.

References

1. Aughsteeen AA, Almasad JK, Al-Muhtaseb MH. Fibro adenoma of the supernumerary breast of the axilla. *Saudi Med J* 2000; 21:587-9.
2. Dixon JM, Mansel RE. ABC of breast diseases. Congenital problems and aberrations of normal breast development and involution. *BMJ* 1994; 309:797-800.
3. Grossl NA. Supernumerary breast tissue: Historical perspectives and clinical features. *South Med J* 2000; 93:29-32.

4. Craigmyle MB. *The Apocrine Glands and the Breast*. Chichester: Wiley; 1984.
5. Kazakov DV, Spagnolo DV, Kacerovska D, Michal M. Lesions of anogenital mammary-like glands: An update. *Adv Anat Pathol* 2011; 18:1-28.
6. Pardo M, Silva F, Jiménez P, Karmelic M. Mammary carcinoma in ectopic breast tissue. A case report. *Rev Med Chil* 2001; 129:663-5.
7. Gugliotta P, Fibbi ML, Fessia L, Canevini P, Bussolati G. Lactating supernumerary mammary gland tissue in the vulva. *Appl Pathol* 1983; 1:61-5.
8. Odike MA, Orakwe JC, Oguejiofor OC, Odenigbo UC, Onyiaorah IV. Axillary fibro adenoma mimicking lymphadenopathy. *Niger J Clin Pract* 2008; 11:72-3.
9. Tresserra F, Grases PJ, Izquierdo M, Cararach M, Fernandez-Cid A. Fibroadenomaphyllodes arising in vulvar supernumerary breast tissue: Report of two cases. *Int J Gynecol Pathol* 1998; 17:171-3.
10. De Cholnoky T. Accessory breast tissue in the axilla. *N Y State J Med* 1951; 51:2245-8.
11. Goyal S, Puri T, Gupta R, Julka PK, Rath GK. Accessory breast tissue in axilla masquerading as breast cancer recurrence. *J Cancer Res Ther* 2008; 4:95-6.
12. Kazakov DV, Spagnolo DV, Stewart CJ, Thompson J, Agaimy A, Magro G, et al. Fibro adenoma and phyllodes tumors of anogenital mammary-like glands: A series of 13 neoplasms in 12 cases, including mammary-type juvenile fibro adenoma, fibro adenoma with lactation changes, and neurofibromatosis-associated pseudoangiomatous stromal hyperplasia with multinucleated giant cells. *Am J Surg Pathol* 2010; 34:95-103?

13. Giron GL, Friedman I, Feldman S. Lobular carcinoma in ectopic axillary breast tissue. *Am Surg* 2004; 70:312-5.
14. Nayak S, Acharjya B, Devi B. Polymastia of axillae. *Indian J Dermatol* 2007; 52:118.
15. Rahbar F. Clinical significance of supernumerary nipples in black neonates. *ClinPediater (Phila)* 1982; 21:46-7.
16. Coras B, Landthaler M, Hofstaedter F, Meisel C, Hohenleutner U. Fibro adenoma of the axilla. *DermatolSurg* 2005; 31:1152-4.