

**Intraoral Lipoma - A Rare Case Report**

¹ Dr.I. Ilangani, Post Graduate student, Department of oral medicine and radiology, SRM dental college, Bharathi salai, Ramapuram, Chennai, Tamil nadu – 600089.

² Dr. Kanmani. R, Senior Lecturer, Department of oral medicine and radiology, SRM dental college, Ramapuram, Chennai, Tamil nadu – 600089.

³ Dr. Anandi. M. S, Senior Lecturer, Department of oral medicine and radiology, SRM dental college, Ramapuram, Chennai, Tamil nadu – 600089.

⁴ Dr. Kannan. A, Professor, Department of oral medicine and radiology, SRM dental college, Ramapuram, Chennai, Tamil nadu – 600089.

⁵ Dr. P. H. Raghuram, Head of the Department, Department of oral medicine and radiology, SRM dental college, Ramapuram, Chennai, Tamil nadu – 600089.

Correspondence Author: Dr. I. Ilangani, Post Graduate Student, Department of Oral Medicine And Radiology, SRM Dental College, Bharathi Salai, Ramapuram, Chennai, Tamil Nadu – 600089.

Conflicts of Interest: Nil

Abstract

Lipoma is a common benign tumour of mesenchymal tissues of body with a rare occurrence in the oral cavity. The commonest intra oral site of lipoma is buccal mucosa followed by tongue, retromolar region, buccal vestibule and floor of mouth. Here, we present a case of intra oral lipoma in the labial mucosa which was surgically excised under local anaesthesia and sent for histopathological examination. The histopathological examination showed mature adipocytes arranged in sheets which helped us to confirm the diagnosis of lipoma.

Introduction

Lipomas are the most common soft tissue mesenchymal neoplasms rarely seen in the oral cavity (1–4% cases) ¹. Intraoral lipoma was first described by Roux in 1848, to which he referred to as “yellow epulis.” ² The lesion may be pedunculated or sessile and occasionally with surface bosselation. The most common intraoral site for lipoma is buccal mucosa, floor of mouth and tongue. ¹ The lesions

are commonly seen in adults with equal distribution in males and females. ² Lipomas can be attributed to mechanical, endocrine, and inflammatory influences, which may lead to the differentiation of multipotent mesenchymal cells in fat tissue, cartilage, and bone. Systemic and local influences such as local trauma or prolonged ischaemia also causes modification of mesenchymal cells. Its differentiation from other mesenchymal tumours is mandatory for diagnosis and treatment planning. ³ Here is a report of this uncommon clinical entity involving left labial mucosa in a male patient along with clinical and histopathological features with no recurrence on follow-ups.

Case report

A 67 year old male patient reported to the department of Oral Medicine and Radiology with a chief complaint of an intra oral growth in the left cheek for past 1 year. The patient first noted a small soft swelling 1 year back which gradually increased to the present size. No pain, discharge,

rupture, recurrences, difficulty in speech and functions were noted. Since the swelling was asymptomatic he did not report to the physician. Patient gives a history of cheek biting habit for past 20 years. The medical history and systemic review were not relevant. On general examination, the patient was moderately built with no facial asymmetry and lymphadenopathy [Figure 1]. Intra oral examination revealed a single, sessile, well defined growth measuring about 0.7 x 0.6 cm in size in the left labial mucosa near the commissure of lips extending superiorly 3cm from the upper labial vestibule, inferiorly 3cm from the lower labial vestibule and posteriorly 4 cm from the retro molar region. The overlying mucosa appears apparently normal [Figure 2]. On palpation, the growth is soft, non tender, and not reducible. Slip sign was negative. A provisional diagnosis of traumatic fibroma was made based on the history and clinical examination.

Routine investigations such as blood pressure, complete blood count, blood sugar levels (fasting and post prandial) and urinalysis were all within the normal limits. The lesion was surgically excised under local anaesthesia and sent for histopathological examination [Figure 3]. The H & E stained tissue section showed mature adipocytes arranged in sheets which were separated by thin fibrous connective tissue. The adipocytes were polyhedral to round in shape with clear to pale cytoplasm and eccentrically placed hyper chromatic nuclei [Figure 4]. Based on the above findings, a final diagnosis of intra-oral lipoma was given. The wound healed uneventfully when the patient was reviewed for suture removal after a week. The patient is under regular follow-ups.

Discussion

Lipomas are benign mesenchymal neoplasms of mature adipocytes mostly occurring in subcutaneous tissue, rarely in deep tissues and oro-maxillofacial regions. Hypertrophy theory suggests that the obesity and inadvertent growth of

adipose tissue are contributory to the formation of these lesions¹¹. The fat from lipomas is not used up in general metabolism during periods of starvation like fat from normal adipose tissue. Metaplasia theory suggests that lipomatous development occurs due to aberrant differentiation of mesenchymal cell-lipoblast. Lin and Lin suggest that lipomas are congenital lesions arising from embryonic multipotent cells. The factors contributing for etiology of lipomas as enumerated by Enzinger and Weiss include chromosomal abnormality like translocation of (3:12) (q127:q13) and (3:12) (28:q14), diabetes mellitus, hypercholesterolemia and obesity.^{6,10} The peak incidence of age for lipomas is fourth to fifth decades of life. Prevalence does not differ with gender, although a slight male predilection has been recorded for oral lipomas in the literature.

Clinically, oral lipomas generally present as mobile, painless submucosal nodules, with yellowish tinge.^{1,7} Superficial lipomas in oro - maxillofacial regions can be clinically diagnosed with the help of palpation, but deep lesions adherent to muscle or salivary gland require imaging techniques such as computerized tomography, magnetic resonance imaging and ultrasonography.⁶

Although, the final diagnosis was made by the typical nature of the gross specimen and microscopic examination. Lipomas can be classified on the basis of histological features as classic lipoma, fibro lipoma, angiolipoma, spindle cell lipoma, and pleomorphic, myxoid, sialolipoma, and intra- muscular lipomas.⁸

The occurrence of multiple lipomas is associated with Cowden's syndrome or multiple hamartoma syndromes, neurofibromatosis, Gardner Syndrome, encephalo craniocutaneous lipomatosis, multiple familial lipomatosis, Proteus Syndrome and Pai syndrome, Dercum's disease.^{7,9}

The present case was simple lipoma with mature fat cells in connective tissue stroma. The fat cells of lipomas are similar to surrounding normal fat cells but larger in size.¹¹ The treatment of choice for oral lipomas is simple surgical excision. There are only exceptional chances of recurrence. Although the growth of oral lipomas is usually limited, they can reach great dimensions, interfering with speech and mastication and reinforcing the need for excision.⁵ In our case, the lesion was small in size without any functional complaint. Still surgical excision was done because of the patient's concern due to the presence of an intraoral growth.

Conclusion

As it is mostly asymptomatic, patients do not seek treatment for lipoma. Though the features of lipoma are simple, accurate clinical examination, surgical excision and histopathological examination is necessary for its definitive diagnosis. Thus clinicians must be aware of occurrence of lipoma in oral cavity and should consider it in the differential diagnosis of any other asymptomatic soft swellings.

References

- [1]. Intraoral Lipoma: Rare Case report with clinical and histopathological study Amit Mohan , Ashim Aggarwal , Shivani Aggarwal.
- [2]. Fibrolipoma: A rare entity - Case series Kavita A Amale, Narendra T Chaudhari¹, Sweety S Bafna¹, Hemant R Umarji
- [3]. Lipomas of Oral and Maxillofacial Region: A Case Series Priya S. Joshi, Madhuri Chougule, Mahesh P. Dudanakar, Bhagyalaxmi P. Hongal, Neha S.
- [4]. Oral lipoma: An uncommon clinical entity Suresh K. Sachdeva, Purnendu Rout¹, Sanjay Dutta², Pradhuman Verma.

- [5]. Osteolipoma : a rare tumour in the oral cavity. Sheyla Viana Omonte, DDS, Bruno Augusto Benevenuto de Andrade, DDS, MS, PhD.
- [6]. Fregnani ER, Pires FR, Falzoni R, Lopes MA, Vargas PA. Lipomas of the oral cavity: clinical findings, histological classification and proliferative activity of 46 cases. Int J Oral Maxillofac Surg. 2003
- [7]. Rao GS, Chatra L, Shenai P. Intra-oral lipoma – A rare entity. Int J Anat Radiol Surg 2013;
- [8]. Chidzonga MM, Mahomva L, Marimo C. Gigantic tongue lipoma: a case report. Med Oral Patol Oral Cir Bucal. 2006
- [9]. Oral lipoma: Many features of a rare oral benign neoplasm L Tettamanti, L Azzi, F Croveri, L Cimetti, D Farronato, G P Bombeccari, A Tagliabue, F Spadari.
- [10]. De Castro AL, de Castro EV, Felipini RC, Ribeiro AC, Soubhia AM. Osteolipoma of the buccal mucosa. Med Oral Patol Oral Cir Bucal. 2010.
- [11]. Amaral MB, Borges CF, de Freitas JB, Capistrano HM, Mesquita RA. Osteolipoma of the oral cavity: a case report. J Maxillofac Oral Surg. 2015.
- [12]. A rare presentation of lipoma on mandibular mucogingival junction Gaurav Sharma, Kanu Jain, Archana Nagpal, Chandrababu Sudha Baiju.

Figure 1 - Extra oral photograph of the patient showing no gross facial asymmetry.



Figure 2 - The single, sessile, well defined intra oral growth.

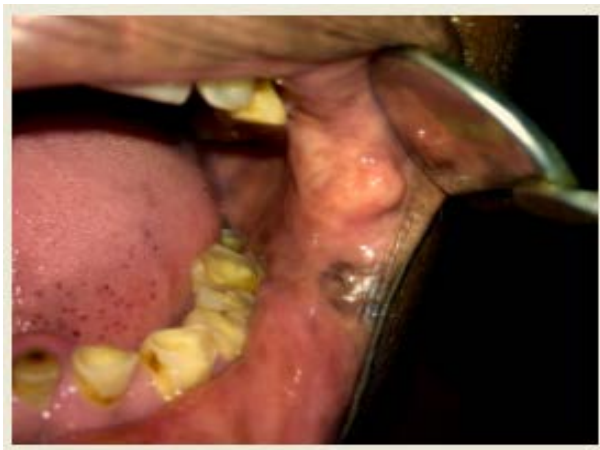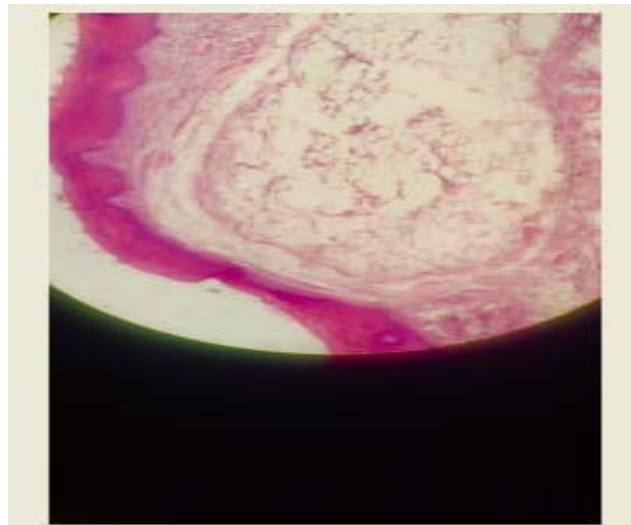


Figure 3 - The excised specimen.




Figure 4 - The histopathological page showing mature adipocytes arranged in sheets separated by thin fibrous connective tissue.