

**Craniofacial Fibrous Dysplasia: A case report and Review**

<sup>1</sup>Dr. Sahuthullah Yasmeenahamed, Reader – Vivekanandha dental college for women, Tamilnadu, India

<sup>2</sup>Dr. Pazhani Ambiga, Sr. Lecturer – Vivekanandha dental college for women, Tamilnadu, India

<sup>3</sup>Dr. Mani Sudhaamani, Professor – Vivekanandha dental college for women, Tamilnadu, India

<sup>4</sup>Dr. Shivakumar Sivaraman, Sr. Lecturer – Vivekanandha dental college for women, Tamilnadu, India

**Correspondence Author:** Dr. Shivakumar Sivaraman, Sr. Lecturer – Vivekanandha dental college for women, Tamilnadu, India

**Conflicts of Interest:** Nil

**Abstract**

Fibrous dysplasia is a developmental tumor like condition that is characterized by replacement of normal bone by excessive proliferation of cellular fibrous connective tissue intermixed with irregular bony trabeculae. Fibrous dysplasia is a benign, relatively common disease distinct from other fibro-osseous lesions. It causes bone pain, deformities & pathologic fracture. In most cases, the disease affects only one bone i.e. monostotic type, however, multiple bones can be involved i.e. polyostotic type. When the monostotic type occurs in the craniofacial region, it is called craniofacial fibrous dysplasia (CFD). Here we discuss a case of craniofacial fibrous dysplasia.

**Keywords:** Fibrous dysplasia, Maxilla, Craniofacial fibrous dysplasia.

**Introduction**

Fibrous dysplasia (FD) is classified as a benign fibro osseous lesion in which there is a disturbance of bone metabolism where the fibrous connective tissue containing abnormal bone replaces normal bone [1]. Fibrous dysplasia is a sporadic benign skeletal disorder which affect one bone (monostotic form) or multiple bones

(polyostotic form). Male and female prevalence of FD is equal. The monostotic form is most common and affects 2<sup>nd</sup> decade while the polyostotic form affects children less than 10 years of age [2]. As earlier said Fibrous dysplasia is a developmental tumor like sporadic condition which results from a post zygotic mutation in GNAS1 (Guanine Nucleotide binding Protein,  $\alpha$ - stimulating activity polypeptide 1) gene [3-4]. Gene GNAS1 codes for G protein which stimulates cAMP production in affected tissue; which causes (1) Endocrinal disturbances which leads to precocious puberty, hyperthyroidism, growth hormone and over production of cortisol (2) Increased proliferation of melanocyte which leads to café-au-lait spots (3) Aberrant activity during osteoblasts differentiation, results in normal medullary bone where it is replaced by fibrous tissue and appears radiolucent on the radiograph [3].

**Case Report**

A 12 year old patient came to the dental op with the complaint of painless swelling in the left middle third of the face for past 3 years. The swelling was small in size initially which increases in size gradually to attain the present state. On extra oral examination the swelling which is of 5\*6 cm approximately that extends medially

1cm away from left ala of the nose to laterally 2cm away from left tragus of the ear and superoinferiorly 1cm below the outer orbital rim to left corner of lip. On palpation consistency was hard, non tender with no rise in temperature (fig 1). On intra oral examination swelling extends from attached Gingiva of 23 to attached gingival of 27 of size 3.5\*6 cm approximately with buccal cortical plate expansion. The mucosa appears normal to adjacent mucosa with no secondary changes. The consistency is hard and non tender (fig 2). The differential diagnosis to be considered is fibro osseous lesions like fibrous dysplasia, ossifying fibroma and osteoma. Biochemical values showed alkaline phosphates 85 IU/l, Serum Calcium 9.2mg% & Serum Phosphorus 3.4 mg % which were within normal range. Radiological investigation includes CT and Orthopantomogram (OPG). CT scan axial section (fig 3) revealed hyper dense area extending from left lateral incisor region to the tuberosity region on the left side and OPG shows gross radio-opacity in the maxillary bone from left lateral incisor region to tuberosity region (fig 4). Biopsy was performed and the tissue was sent for histopathological examination. The sections reveals "C" shaped bony trabeculae in a highly cellular connective tissue. The trabeculae showed presence of osteocytes and absence of peripheral rimming of osteoblasts suggestive of fibrous dysplasia (Figures 5). The lesion was surgically excised ( figure 6 ) and patient was followed at regular intervals and there was no recurrence.

### **Discussion**

Fibrous dysplasia "a benign lesion, usually developmental in nature, characterized by the presence of fibrous connective tissue with a defined whorled pattern and containing trabeculae of immature nonlamellar bone" [5]. Author Eversole defines craniofacial bones of fibrous dysplasia as "a benign, non neoplastic intramedullary

cellular proliferation of fibroblasts, which is formed by irregular trabeculae of bone or ovoid calcifications which shows indistinct, non encapsulated borders" [5]. Fibrous dysplasia is a condition which is hamartomatous or disorder of bone metabolism [6]. The monostotic form of fibrous dysplasia generally affects the second decade of life. The craniofacial form occurs in early 1<sup>st</sup> decade of life and it is more severe, and then progresses throughout adolescence [7]. Our case of craniofacial fibrous dysplasia correlates with this author. The other subtypes of polyostotic dysplasia shows cafe-au-lait pigmentation and endocrinopathies where they are called Jaffe-Lichtenstein syndrome and McCune-Albright syndrome. Fibrous dysplasia can be diagnosed based on clinical, radiographic, and histopathological findings [7]. Patient is usually seen with abnormal enlargement of maxillofacial region without pain or infection, "ground-glass" pattern seen in radiographic film and "C shaped bony trabeculae" or "fish bone" woven bone patterns seen in a microscopic view are also classical characteristics [6, 8]. This case also proves to be same as the author with painless swelling and with histopathological feature. Mirra supported a concept, which stated, "when a single bone (monostotic) is affected, it probably represents a forme fruste of the more severe form (polyostotic)." He stated that the craniofacial bones affected fibrous dysplasia are in the following order that is frontal > sphenoid > ethmoid > maxilla > mandible > zygoma > parietal > occipital > temporal [5]. The normal serum alkaline phosphatase level may indicate that the disease might have now entered a stationary phase. However, serum alkaline phosphatase level is not always raised in fibrous dysplasia (9), and does not, therefore, rule out continued osteoblastic activity. Sudden elevation in the level of alkaline phosphatase is the symptoms for malignant transformation and for that reason its amount should be checked periodically. In this

case there is no elevated serum alkaline phosphatase level. Malignant changes of fibrous dysplasia include Osteosarcoma, Fibrosarcoma, Chondrosarcoma, Malignant fibrous histiocytoma & Ewings sarcoma [10]. Treatment of bony lesions of fibrous dysplasia includes surgical and nonsurgical therapies. Surgical treatment of young-aged minor cases include biopsy with minor bony osteoplasty at the affected site is sufficient. In more severe cases complete excision with graft reconstruction may be possible [11]. Useful biomarkers such as serum alkaline phosphatase and urinary hydroxyproline are used to monitor in the nonsurgical treatment of the disease rather for diagnosis [12, 13]. Therefore in this case the clinical features, radiographic features, and histopathological features were correlated to come to a final decision of fibrous dysplasia. Fibrous dysplasia usually get stabilized after puberty [10]. In this case surgical excision of the lesion is done for esthetic concern.

### Conclusion

Fibrous dysplasia may manifests as monostotic or polyostotic form. Diagnosis of polyostotic form are easy due to extra-skeletal involvement. Monostotic form are usually common in the jaw. Fibrous dysplasia is a tumor like developmental disorder with minimal chances of malignancies. Our case has not shown any malignant changes till date and the follow up is still ongoing. In young-aged monostotic fibrous dysplasia cases, regular follow up or minor bony osteoplasty at affected site is adequate for esthetic and functional purpose.

### References

[1]. S. R. Singer, M. Mupparapu, and J. Rinaggio, "Clinical and radiographic features of chronic monostotic fibrous dysplasia of the mandible," *Journal of the Canadian Dental Association*, vol. 70, no. 8, pp. 548–552, 2004.

[2]. L. Feller, N. H. Wood, R. A. Khammissa, J. Lemmer, and E. J. Raubenheimer, "The nature of fibrous dysplasia," *Head and Face Medicine*, vol. 5, no. 1, article 22, 2009.

[3]. Rajendran R, Sivapathasundharam R. Shafer's Textbook of Oral pathology 5th edition, New Delhi, India, Elsevier, a division of Reed Elsevier India Private Limited; 2006; pp 971-979.

[4]. Ricalde P, Horswell BB. Craniofacial fibrous dysplasia of the Fronto- Orbital Region: A Case series and Literature. *J Oral Maxillofac Surg* 2001;59:157-168.

[5]. S. Mahajan, M. Kamboj, and K. Baoz, "Maxillofacial fibrous dysplasia," *Indian Journal of Dental Research*, vol. 16, no. 4, pp. 151–152, 2005.

[6]. B. W. Neville, D. D. Damm, C.M. Allen, and J. Bouquot, *Oral and Maxillofacial Pathology*, WB Saunders, Philadelphia, Pa, USA, 2nd edition, 2002.

[7]. D. MacDonald-Jankowski, "Fibrous dysplasia in the jaws of a Hong-Kong population: radiographic presentation and systematic review," *Dentomaxillofacial Radiology*, vol. 28, no. 4, pp. 195–202, 1999.

[8]. S. O. Akintoye, L. L. Otis, J. C. Atkinson et al., "Analyses of variable panoramic radiographic characteristics of maxillomandibular fibrous dysplasia in McCune-Albright syndrome," *Oral Diseases*, vol. 10, no. 1, pp. 36–43, 2004.

[9]. Pierce AM, Wilson DF, Prabhu SR (1992). Fibroosseous and other lesions of the jaw-bones. In: Prabhu SR, Wilson DF, Daftary DK, Johnson NW (eds). *Oral diseases in the tropics*. Oxford University Press, New York, pp 715–731.

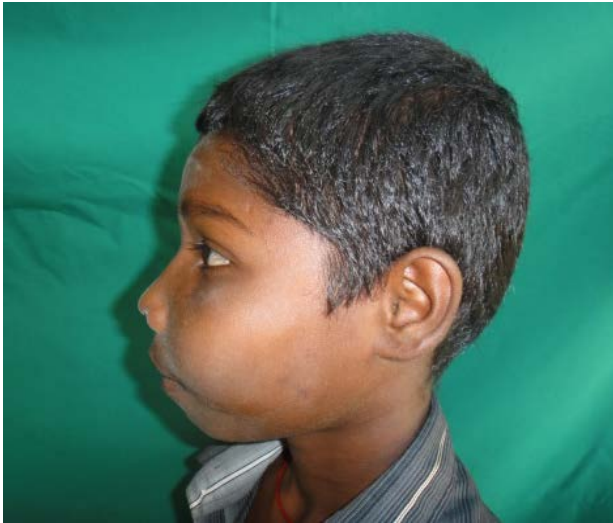[10]. Keskin M, Karabekmez FE, Ozkan BT, Tosun Z, Avunduk MC, Savaci N. Simultaneous occurrence of facial fibrous dysplasia and ameloblastoma. *J Craniomaxillofac Surg* 2009;37:102-105.

[11]. A. T. Moore, J. R. Buncic, and I. R. Munro, "Fibrous dysplasia of the orbit in childhood. Clinical features and management," *Ophthalmology*, vol. 92, no. 1, pp. 12–20, 1985.

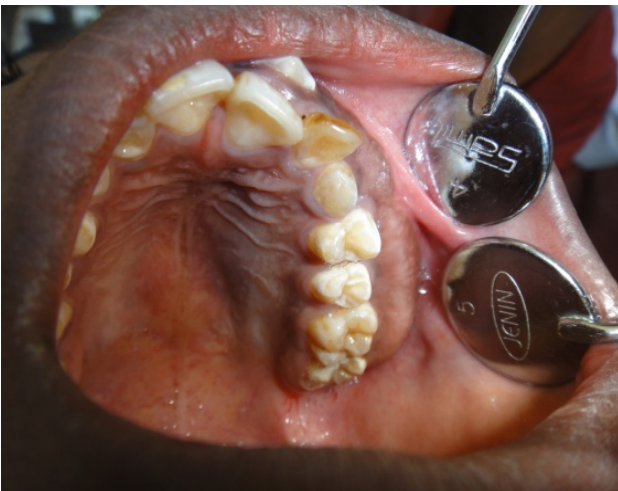
[12]. H. Plotkin, F. Rauch, L. Zeitlin, C. Munns, R. Travers, and F. H. Glorieux, "Effect of pamidronate treatment in children with polyostotic fibrous dysplasia of bone," *Journal of Clinical Endocrinology and Metabolism*, vol. 88, no. 10, pp. 4569–4575, 2003.

[13]. Y. R. Chen, C. N. Chang, and Y. C. Tan, "Craniofacial fibrous dysplasia: an update," *Chang Gung Medical Journal*, vol. 29, no. 6, pp. 543–549, 2006.

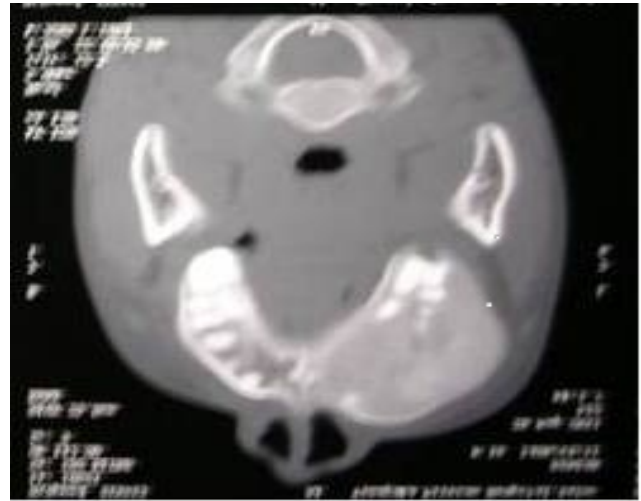
**Figure 1:**



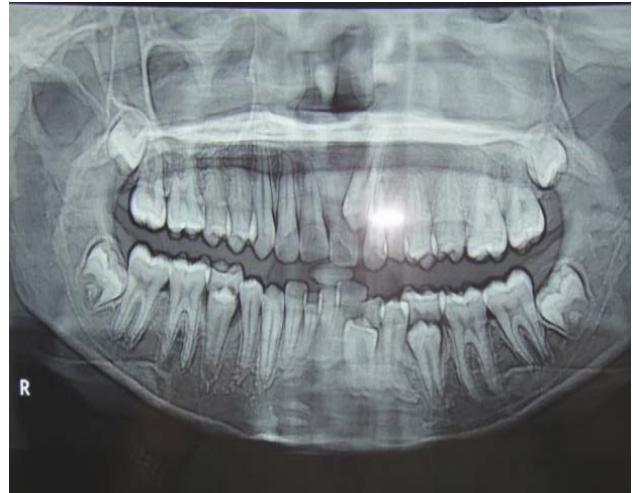**Figure 2:**



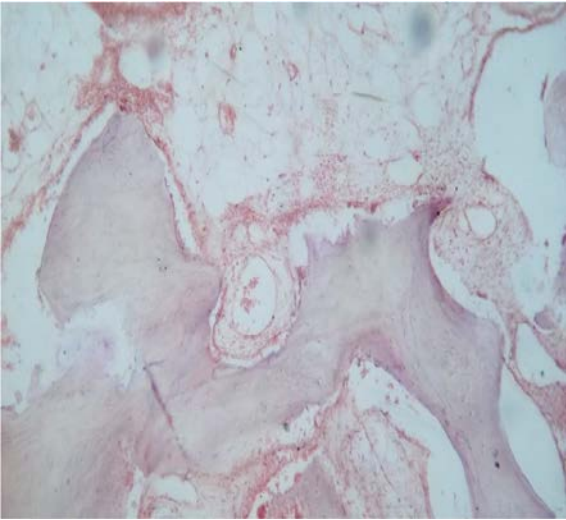
**Figure 3:**



**Figure 4:**



**Figure 5:**



**Figure 6:**

