

**Functional Evaluation of Arthroscopic Repair of Meniscal Tear in Adults**

Amit Meena - M.S. Orthopaedics, Central Institute of Orthopaedics, Vardhaman Mahavir Medical College and Safdarjung Hospital

B P Sharma - M.S. Orthopaedics, Consultant and Associate Professor, Unit Head (Arthroscopy Unit)

Sumon S Saikia - M.S. Orthopaedics, Central Institute of Orthopaedics, VMMC & SJH

Rahul Grover - M.S. Orthopaedics, Central Institute of Orthopaedics, VMMC & SJH

Gaurav Singh - M.S. Orthopaedics, Central Institute of Orthopaedics, VMMC & SJH

Manoj Kumar - M.S. Orthopaedics, Central Institute of Orthopaedics, VMMC & SJH

Correspondence Author: B P Sharma - M.S. Orthopaedics, Consultant and Associate Professor, Unit Head (Arthroscopy Unit).

Address - Central Institute of Orthopaedics, Vardhaman Mahavir Medical College and Safdarjung Hospital, New Delhi - 110029

Conflicts of Interest: Nil.

Abstract

Purpose: The purpose of this study was to assess the functional outcomes of arthroscopic meniscal repairs.

Type of Study: Prospective study.

Methods: Thirty consecutive meniscal repairs were performed from June 2015 to May 2017 using the all-inside and outside-in technique. All tears were located at red-red or red-white zones. Preoperative and follow-up evaluation was performed using the objective and subjective International Knee Documentation Committee (IKDC) criteria as well as Lysholm functional questionnaires. Presence of locking, joint-line tenderness, effusion, and positive McMurray test were considered to indicate clinical failure. Statistical significance was determined using paired t-test between pre and post. A p value of <0.05 was considered statistically significant.

Results: The patient population studied, had an average age of 28.13 ± 6.34 [mean \pm S.D.] years (range, 18 to 42 years), and a follow-up of 1 year. There were 20 male and 10 female patients with 24 medial and 6 lateral repairs. All-inside technique performed in 24 patients and outside-

in performed in 6 patients. The success rate by IKDC score was 90% [excellent result in 22 patients (73.33%), good result in 5 patients (16.67%), fair result in 3 patients (10 %)]. Both the subjective IKDC and the Lysholm scores statistically improved. Mean (\pm SD) preoperative IKDC score was $48.8 (\pm 10.66)$ and post-operative mean (\pm SD) IKDC score at 1 year was $86.9 (\pm 10.63)$. Pre-operative Mean \pm SD of Lysholm score was 57.3 ± 12.58 and post-operative Mean \pm SD was 82.47 ± 16.54 .

Conclusion: Arthroscopic meniscal repair improves functional outcome.

Keywords Meniscus, Meniscus repair, All-inside and Outside-in technique, Arthroscopy, Outcomes

Introduction

The menisci, once thought as a vestige of leg muscle, have been considered as a vital structure with various functions: chondroprotection through weight distribution by enlarging the contact area between the femur and the tibia⁽¹⁾, weight bearing⁽²⁾, joint stabilization⁽³⁾, joint lubrication⁽⁴⁾, articular cartilage nutrition⁽⁵⁾, proprioception⁽⁶⁾, load-transmission and energy-absorption⁽⁷⁾. Menisci have an important role

in knee function. Long-term follow-up studies showed that virtually all meniscectomized knees develop arthritic changes with time⁽⁸⁾. Moreover, the severity of these changes seems to be proportional to the amount of meniscus removed. Because of these functions, meniscal tissue should be preserved whenever possible.

Meniscal injury is a common source of pain and functional impairment of the knee that is frequently encountered by orthopaedic surgeons⁽⁹⁾. The Meniscal tears are the most common pathology of the knee with a mean annual incidence is about 60–70 per 100,000^(10, 11) with a male to female ratio ranging from 2.5:1 to 4:1. They may occur in acute knee injuries in younger patients or as part of a degenerative process in older individuals. Medial meniscal tears occur more frequently than tears of the lateral meniscus, at a ratio of approximately 2:1⁽¹²⁾.

Historically it was believed that the menisci served no functional purpose and they were often excised with open total meniscectomy. In 1948 Fairbank reported the clinical outcomes of 107 patients after total meniscectomies and found that the majority had progressive flattening of the condyle, narrowing of the joint space and ridge formation⁽⁸⁾. This study significantly changed our approach to dealing with meniscal tears. Maintaining an intact and functioning meniscus is felt to be a major factor in reducing the ultimate risk of progression to radiographic findings consistent with arthritis. Thus, by maintaining physiologic knee kinematics as best as possible, we aim to prevent, or at least delay, the premature onset of osteoarthritis.

Meniscal repair can be performed either with an open or arthroscopic technique. Arthroscopic meniscal repair has advantages over open repair in terms of minimal incision, early recovery and rehabilitation⁽¹³⁾. Arthroscopic repair can be done by inside-out techniques, outside-in

techniques, all-inside techniques and hybrid techniques that combine multiple techniques⁽¹⁴⁾.

The goals of surgical intervention for meniscal tears are to relieve pain, facilitate pre-injury level daily living activities, and prevent early degeneration of the knee joint⁽¹⁵⁾. Some surgeons have performed meniscal repairs even in more than 60 years of age⁽¹³⁾. The reparability of meniscal tears depends on several factors, such as vascularity, type of tear, chronicity, and size⁽¹⁴⁾.

Materials and methods

The study was conducted at Central Institute of Orthopaedics, Vardhman Mahavir Medical College and Safdarjung hospital, New Delhi. In this prospective study 30 patients with suspicion of a meniscal tear (based on clinical examination and magnetic resonance imaging (MRI)) were asked to enroll in the study after informed consent if they met the following criteria: (a) longitudinal full thickness tear greater than 10 mm in length, (b) location of the tear less than 6 mm from the meniscocapsular junction, (c) no former meniscus surgery, (d) no evidence of arthritis during arthroscopy, (e) no concomitant ligamentous injury and (f) fixation of the meniscus using only one technique (no hybrid fixation). From June 2015 to May 2017, 30 meniscal tears were repaired in 20 men and 10 women. The age of the patients at the time of meniscal repair was 28.13 ± 6.34 [mean \pm S.D.] years (range, 18 to 42 years). This was a prospective study where patients were followed up to 1 year. The meniscal tears involved 16 right knees and 14 left knees, and the tears were located in 24 (80 %) medial and 6 lateral menisci (20 %). All tears were vertical, located in the red–red or red–white zone. Twenty four repairs were carried out using in-side out repair technique and 6 repair needed outside-in technique. Preoperative and follow-up evaluation was performed using the objective and subjective International Knee Documentation Committee

(IKDC) criteria as well as Lysholm functional questionnaires. Presence of locking, joint-line tenderness, effusion, and positive McMurray test were considered to indicate clinical failure. Statistical significance was determined using paired t-test between pre and post. A p value of <0.05 was considered statistically significant. After repair, the involved leg was placed in a brace for 4 weeks. Full weight bearing was immediately allowed with the brace in full extension. Flexion was limited to 90° during 4 weeks. Running, swimming, and cycling were begun at 3 months. Return to full athletic participation was authorised at 6 months.

Surgical Techniques

General anesthesia or spinal anesthesia was administered to all patients. After diagnostic arthroscopy, the morphology of the meniscus tear was determined. The tear length and the rim width were recorded at the time of surgery. Tear edges were freshened with a meniscus rasp and shaver. Using microfracture awls, multiple perforations were made in the meniscus rim to produce vascular channels and encourage bleeding to stimulate the healing response. We used an all-inside technique for placing suture in the posterior or middle segments and an outside-in technique for the middle or anterior segments of the meniscus.

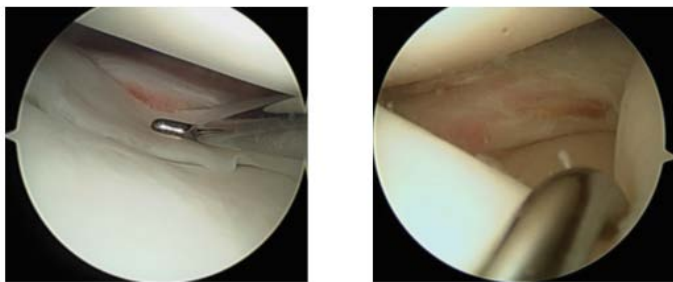


Figure1: Peripheral, longitudinal tears of the lateral meniscus arthroscopic view using the probe to assess stability.

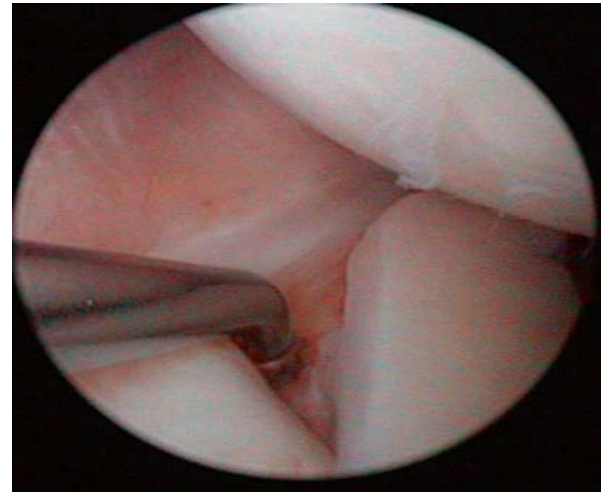


Figure2: Meniscal abrasion with a rasp

Case 1:

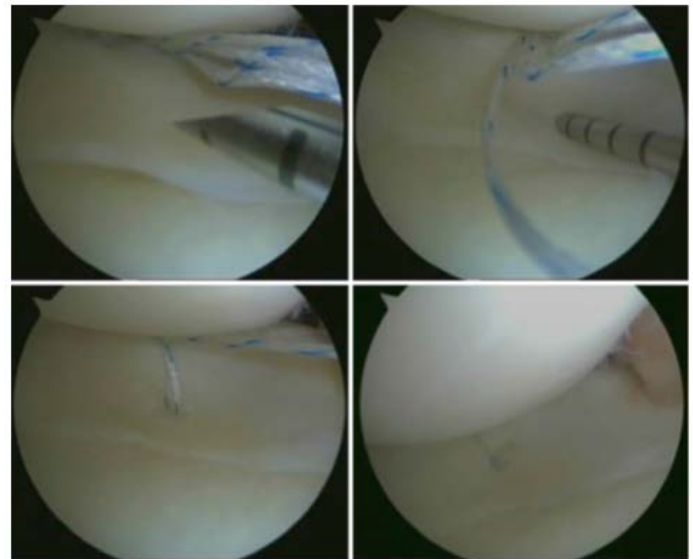


Figure3: showing All-inside meniscal repair with vertical suture

Case 2:

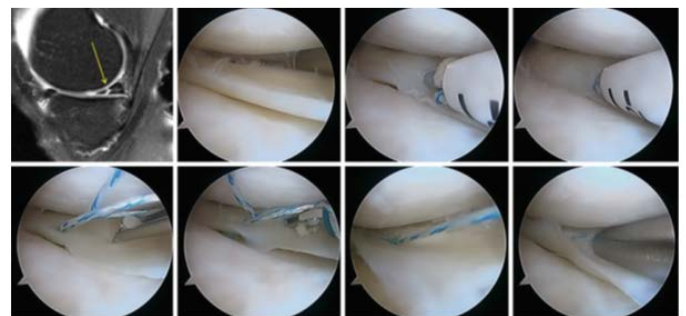


Figure4: MRI of longitudinal tear and arthroscopic view, all-inside repair sequence with the first anchor

introduction than the second anchor is deployed than the suture is finally tensioned by pulling the suture and then by the use of a knot pusher.

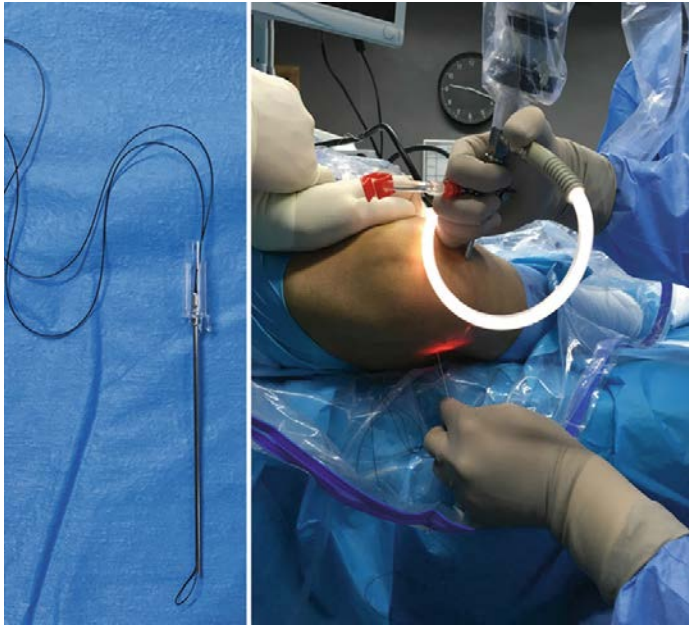

Figure5: showing Needle with nylon loop used to retrieve sutures for outside-in repair. Introduction from outside to the inside of the joint at the level of joint line by transillumination and direct arthroscopic view.

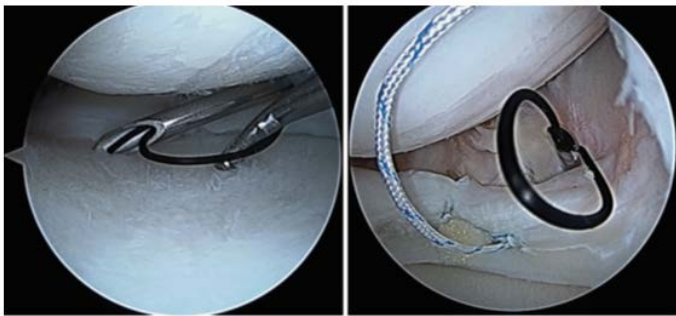


Figure6: showing Arthroscopic view of outside-in technique. The nylon loop is used to bring the suture outside the joint percutaneously before final suture which requires a small stab skin incision.

Results

Non sporting activity was the most common cause of meniscal tear with 12 patients, sporting injury was second common with 10 patients and atraumatic injuries were the least common cause of meniscal tear with 8 patients. Joint

line tenderness along with locking and catching were common clinical feature in majority of patients. We preferred all inside meniscal repair technique in 24 patients due to ease of use, avoidance of an accessory incision, shorter operating time, and less risk to neurovascular structures and in 6 patients where tear was not amenable to repair by all-inside technique specially tears located in anterior horn of meniscus, we used Outside- in meniscal repair technique. In our study preoperative mean (\pm SD) IKDC score was 48.8 (\pm 10.66) and post operative mean (\pm SD) IKDC score at 1 year was 86.9 (\pm 10.63) and the change in IKDC score was statistically significant (p value 0.0001). After 1 year of follow up we got excellent result in 22 patients (73.33%), good result in 5 patients (16.67%), and fair result in 3 patients (10 %) according to IKDC score. In our study Pre operative mean (\pm SD) Lysholm score was 57.3 (\pm 12.58) and post operative mean (\pm SD) score at 1 year was 82.47 (\pm 16.54) with a p value of $<$.0001 which was statistically significant (p value $<$ 0.05). After 1 year of follow up we got excellent result in 15 patients (50%), good result in 12 patients (40%), and fair result in 3 patients (10 %) according to Lysholm score. Although all-inside technique had the advantage of avoiding neurovascular complications but implant related complication was seen. Out of 30 patients, complications were observed in 2 patients (6.66%), out of these two, one patient had neuropraxia of the peroneal nerve during outside in technique which recovered spontaneously and in other patient device launch inaccurately during all-inside technique. An appropriate rehabilitation protocol was necessary to optimize the results.

Discussion

In the study conducted by Haas AL et al in 2005 the Subjective IKDC scores improved significantly (P $<$.05). Thirty-three of 37 patients (89%) had good to excellent

results on their postoperative subjective⁽¹⁶⁾. In 2012 Albertoni LJB et al conducted study in which 82% of the cases (18 patients) were considered to have well to excellent results, 18% were fair and none were poor. The change in pre-operative and post-operative IKDC score was statistically significant (p value 0.001)⁽¹⁷⁾. August W M Fok et al found that mean IKDC score improved significantly from 62 preoperatively to 81 postoperatively (P<0.001, paired *t* test) in their study in 2013⁽¹⁸⁾. Our result for IKDC score was similar to the previous studies which all showed increased in IKDC score post-operatively

In the study conducted by Haas AL et al in 2005 the Lysholm scores statistically improved (P<.05) from 69.35 (SD ± 11.85) preoperatively to 93.73 (SD ± 6.58) postoperatively⁽¹⁶⁾. In the study conducted by Chiang CW et al in 2010 the Lysholm score improved significantly (p <0.0001) from an average of 65 (SD± 5) preoperatively to 95 (SD± 9) postoperatively⁽¹⁹⁾. In the study conducted by Albertoni LJB et al in 2012 the pre operative Lysholm score was 55.82 which significantly improved post operatively to 89.95 (p value 0.001)⁽¹⁷⁾. In the study conducted by Keyhani S et al in 2014 the outcome of the Lysholm score was excellent and good in 49 (80.3%) patients and fair in 12 (19.7%)⁽²⁰⁾.

Our result for Lysholm score was similar to the previous studies which all showed increased in Lysholm score postoperatively

Conclusion

We concluded that arthroscopic meniscal repair improved functional outcome of knee for vertical full-thickness tear greater than 10 mm in length, located less than 6 mm from the meniscocapsular junction.

References

- [1]. Seedhom BB, Dowson D, Wright V. Proceedings: functions of the menisci. A preliminary study. *Ann Rheum Dis.* 1974; 33:111.
- [2]. Voloshin AS, Wosk J. Shock absorption of meniscectomized and painful knees: a comparative in vivo study. *J Biomed Eng.* 1983;5:157-161.
- [3]. Markolf KL, Mensch JS, Amstutz HC. Stiffness and laxity of the knee--the contributions of the supporting structures. A quantitative in vitro study. *J Bone Joint Surg Am.* 1976; 58:583-594.
- [4]. Mac CM. The movements of bones and joints; the synovial fluid and its assistants. *J Bone Joint Surg Br.* 1950;32:244-252.
- [5]. Renstrom P, Johnson RJ. Anatomy and biomechanics of the menisci. *Clin Sports Med.* 1990;9:523-538.
- [6]. Zimny ML, Albright DJ, Dabezies E. Mechanoreceptors in the human medial meniscus. *Acta Anat (Basel).* 1988;133:35-40.
- [7]. Krause WR, Pope MH, Johnson RJ, Wilder DG. Mechanical changes in the knee after meniscectomy. *J Bone Joint Surg Am.* 1976;58:599-60.
- [8]. Fairbank TJ. Knee joint changes after meniscectomy. *J Bone Joint Surg Am.* 1948;30B:664-670.
- [9]. Clayton RA, Court-Brown CM. The epidemiology of musculoskeletal tendinous and ligamentous injuries. *Injury.* 2008;39:1338-1344.
- [10]. Hede A, Jensen DB, Blyme P, Sonne-Holm S. Epidemiology of meniscal lesions in the knee. 1,215 open operations in Copenhagen 1982-84. *Acta Orthop Scand.* 1990;61:435-437.
- [11]. Nielsen AB, Yde J. Epidemiology of acute knee injuries: a prospective hospital investigation. *J Trauma.* 1991;31:1644-1648.
- [12]. Campbell SE, Sanders TG, Morrison WB. MR imaging of meniscal cysts: incidence, location, and

- clinical significance. *AJR Am J Roentgenol.* 2001;177:409-413.
- [13]. Yoon KH, Park KH. Meniscal repair. *Knee Surg Relat Res.* 2014;26:68–76.
- [14]. Miller III RH, Azar FM. Knee Injuries. In: Canale ST, Beaty JH eds. *Campbell's Operative Orthopaedics.* 12th ed. St Louis, MO: Mosby; 2012:2075-2078.
- [15]. Jeong HJ, Lee SH, Ko CS. Menisectomy. *Knee Surg Relat Res.* 2012;24:129–136.
- [16]. Haas AL, Schepisis AA, Hornstein J, Edgar CM. Meniscal repair using the FasT-Fix all-inside meniscal repair device. *Arthroscopy.* 2005;21:167–175.
- [17]. Albertoni LJB, Schumacher FC, Ventura MHA, da Silveira Franciozi CE, Debieux P, Kubota MS et al. Meniscal repair by all-inside technique with Fast-Fix device. *Rev Bras Ortop Engl Ed.* 2013;48:448-454.
- [18]. August W M Fok, W P Yau. Early results of all-inside meniscal repairs using a pre-loaded suture anchor *Hong Kong Medical Journal.* 2013;19:124-128.
- [19]. Chiang CW, Chang CH, Cheng CY, [Chen AC](#), [Chan YS](#), [Hsu KY](#), et al. Clinical results of all-inside meniscal repair using the FasT-Fix meniscal repair system. *Chang Gung Med J.* 2011;34:298–305.
- [20]. Keyhani S, Abbasian MR, Siatiri N, Sarvi A, Kivi MM, Esmailiejah AA. Arthroscopic Meniscal Repair: “Modified Outside-In Technique.” [Arch Bone Jt Surg.](#) 2015;3:104-108.