



## **A Rare Presentation of Pancytopenia with Hemophagocytosis Lymphohistiocytosis: T cell/ Histiocyte Rich Large B cell Lymphoma – a Case Report**

Mathi Manoj Kumar R <sup>1</sup>, Subramaniam J R <sup>2</sup>, Prabu P <sup>3</sup>

<sup>1,2</sup> Department of General Medicine, <sup>3</sup> Department of Hematology

Apollo Hospitals, Greams Road, Chennai -6.

**Corresponding Author:** Dr Mathi Manoj Kumar R, Department Of General Medicine, Apollo Hospitals, Greams Road, Chennai – 6.

**Type of Publication:** Case Report

**Conflicts of Interest:** Nil

### **Abstract**

T-cell/Histiocyte Rich Large B cell Lymphoma (T/HRLBCL) is a subtype of diffuse large B-cell lymphoma (DLBCL). This variety of lymphoma highlights the challenges in defining and classifying the specific subtypes of DLBCL. Predominantly, it is a nodal disease, with extranodal involvement, such as bone marrow, spleen, and liver. T/HRLBCL is characterized by paucity of large, atypical B-cells and surrounded in the background by a dense population of reactive T-cells and histiocytes. Morphologically, it is very similar to the Nodular Lymphocyte Predominant Hodgkin lymphoma (NLPHL). Hemophagocytic lymphohistiocytosis (HLH) is a clinical condition characterized by disarray of immune system. Cytotoxic T cells and natural killer cells functions are often impaired and most cases of lymphoma-associated with HLH are due to T cell related malignancies. HLH associated with B-cell lymphoma is uncommon. Here report a case of an immunocompetent individual presenting as pancytopenia, with secondary HLH and later diagnosed as a case of T/HRLBCL.

**Keywords:** T-cell/Histiocyte Rich Large B cell

Lymphoma, Hemophagocytic lymphohistiocytosis, Pancytopenia

### **Introduction**

T/HRLBCL accounts for 1-2% of all non-Hodgkin's lymphoma and it is a subtype of diffuse large B-cell lymphoma in the Revised European-American Lymphoma classification and World Health Organisation (WHO) classification <sup>[1]</sup>. According to the WHO classification in 2008, T/HRLBCL is included as specific subtype of diffuse large B cell lymphoma <sup>[2]</sup>. This was first described as “T-cell-rich B-cell lymphoma” by Ramsay et al. in 1988 <sup>[3]</sup>. The definition was later elaborated in 1992 by Delabie et al. <sup>[4]</sup> who coined the term “histiocyte-rich B-cell lymphoma”, describing six cases of large B-cell lymphoma notable for minimal neoplastic B cells amid a prominent infiltrate of histiocytes and small lymphocytes. T/HRLBCL has gained a lot of attention due to the difficult task of distinguishing it from similar neoplasms namely NLPHL and classical Hodgkin's lymphoma (cHL). Such histological similarities infer the possibility of overlapping mechanisms of tumor growth and survival across these lymphoid diseases, and have provided

valuable insight in understanding the relationship between various lymphomas and their microenvironment<sup>[5]</sup>.

### Case Report

A 52 year old gentleman with no co-morbidities was admitted for evaluation and management of pyrexia of unknown origin (PUO). On Admission, he was febrile (101F), tachycardic (121/min). Clinical examination showed hepatosplenomegaly, bilateral pitting pedal edema with bilateral axillary lymphadenopathy, largest being right axillary lymph node measuring 3x2 cm.

Significant laboratory investigations include Pancytopenia - Hb 8.4 gm% (13-18 gm %) WBC Count- $2.3 \times 10^3/\text{mm}^3$  ( $4-11 \times 10^3/\text{mm}^3$ ), Platelet count-  $60000 \times 10^3/\text{mm}^3$  ( $150-450 \times 10^3/\text{mm}^3$ ), PT 15/11 (10-13 seconds), APTT 51/27(21-33 seconds) Ferritin -5827, Triglyceride – 392 (Normal <150 mg/dl) and Reticulocyte count – 6% (0.2-2 %). DCT was 3+, LDH – 1138 (125-220 U/L), Vitamin B<sub>12</sub> levels were normal, HIV, HbsAg, Anti HCV were negative. Lupus anticoagulant was weakly detected.

In the view of pancytopenia, organomegaly, elevated ferritin and triglyceride levels, Hemophagocytosis lymphohistiocytosis (HLH) was suspected and hence Bone marrow examination was considered. Bone marrow aspiration showed hypercellular marrow with increase in macrophages with hemophagocytosis suggestive of HLH. Bone marrow biopsy showed dysplastic megakaryocytes and some atypical cells.

Right sided axillary lymph node biopsy was done and it showed atypical lymphoid cells suggestive of Lymphoma. Lymph node and Bone marrow sample was sent for Immunohistochemistry (IHC) It revealed CD3+,CD20+(large cells),LCA+(large cells),PAX-5+(large cells-weak),BOB-1+(large cells),OCT-2+,PD1a+,CD21+. Block from the bone marrow showed CD20+(few large cells),CD61+ megakaryocytes),CD30+(large cells),LCA+,PAX-5+(large cells),BOB-1+(large cells). The

above features were consistent with T cell/ Histiocyte rich B cell lymphoma.

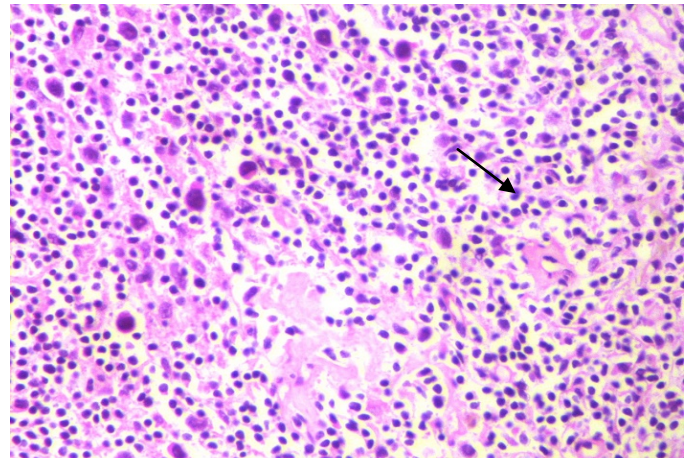


Fig 1 : Axillary Lymph node biopsy atypical lymphoid cells

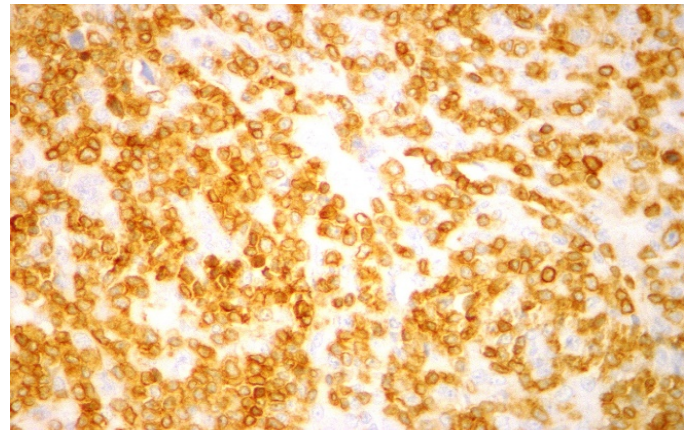


Fig 2: IHC image showing CD3+

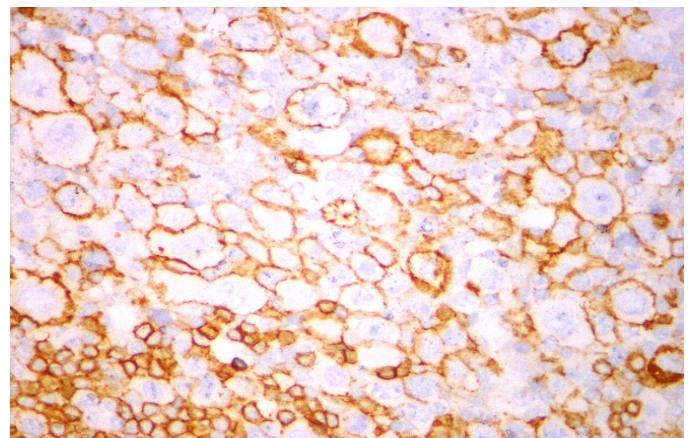
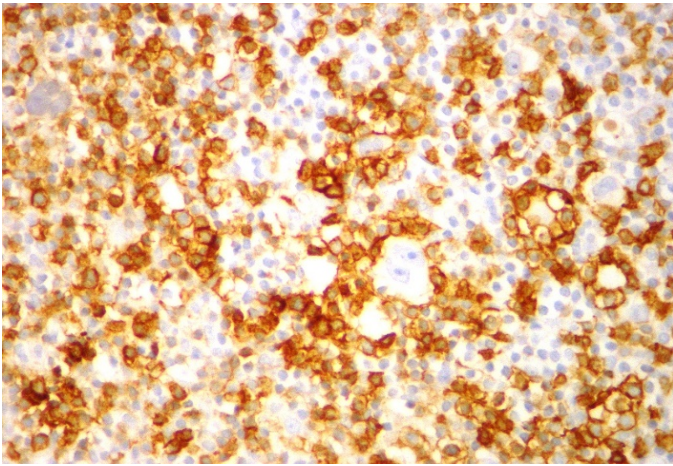


Fig 3: CD 20+ (40x)



**Fig 4: PD 1 (40x)**

He was then started on R-CHOP (Cyclophosphamide, doxorubicin, vincristine and prednisolone) chemotherapy in combination with rituximab regimen and subjected to regular follow up.

### Discussion

T cell Histiocyte Rich Large B Cell Lymphoma (T/HRLBCL) is a rare variant of lymphoma accounting for 1-2% of diffuse large B cell lymphoma (DLBCL). The pathophysiology mainly involves cytokine-mediated evasion of the T cell immune response by the malignant B cells. It is an aggressive lymphoma, presenting at an advanced stage and with extranodal involvement in more than 60% of cases<sup>[6]</sup>. T/HRLBCL occurs at a younger age than traditional DLBCL, with a median age in the fourth decade of life compared with the sixth decade for DLBCLs as a whole. A male predominance has been noted in most case series, contrasting with DLBCL, which occurs roughly equally in men and women<sup>[7, 8]</sup>.

This lymphoma infiltrates the spleen, liver, and bone marrow more often than DLBCL. Bone marrow involvement occurs in approximately one third of patients with T/HRLBCL, which is considerably higher than DLBCL counterparts<sup>[9]</sup>. T/HRLBCL patients also develop “B” symptoms (unexplained fever  $>38^{\circ}\text{C}$ , drenching night sweats, and unexplained weight loss  $>10\%$  of body weight

over a 6-month period), with rates reported as high as 62%<sup>[10]</sup>

Correct diagnosis of T/HRLBCL requires in depth analysis of pathologists in differentiating it from histologically similar spectrum of lymphoproliferative disorders. Neoplastic cells along with inflammatory infiltrate serves as a hallmark of this DLBCL variant. In 2001, WHO defined T/HRLBCL as a morphologic variant of DLBCL characterized by fewer than 10% large neoplastic B cells amid a prominent inflammatory infiltrate, the majority of which are small polyclonal T cells, with or without the presence of histiocytes<sup>[11]</sup>. On low-power examination, the nodal architecture is usually completely effaced with a diffuse pattern of tumor infiltration, though vague nodularity may be apparent, overlapping with NLPHL<sup>[12]</sup>.

On immunohistochemical (IHC) analysis, the malignant B cells of T/HRLBCL are positive for CD45, CD20, and the B-cell transcription factors PAX5/BSAP, OCT2, and BOB1. The cells are uniformly negative for CD15, CD5 and CD138 and only rarely show weak positivity for CD30. Bcl-6 and CD79a are expressed by the majority of tumors. However in our patient it was negative. CD10 is positive in only a minority of cases<sup>[13]</sup>. Bcl-2 expression, a poor prognostic finding in DLBCL<sup>[14, 15]</sup>, has been reported in 14%–50% of tumors, although the classic *IgH/bcl-2* gene rearrangement is uncommon. Epstein-Barr virus association was rarely observed in T/HRLBCL and has been associated with a cHL-like phenotype, leading to a grey area in diagnosis between these entities<sup>[13]</sup>.

Hartmann S et al., in their study have studied the three entities of NLPHL, T/HRLBCL and T/HRLBCL like NLPHL. They analysed the gene expression profiling of these three entities and found BAT 3/BAG 6, HIGD1A AND FAT10/UBD were expressed in all the three lymphomas. They have concluded in their study that

T/HRLBCL like NPLHL behaves more like T/HRLBCL rather than NPLHL<sup>[16, 21]</sup>.

Mangal Pandure et al., have reported a case of THRLBCL presenting as a spinal mass<sup>[17]</sup>. Advani P et al., have reported a rare case of Primary Central Nervous system lymphoma presenting with T/HRLBCL morphology<sup>[18]</sup>.Turkoz HK et al., have reported a case of splenic T/HRLBCL presenting in a micronodular pattern in a previously diagnosed case of small lymphocytic lymphoma of the spleen<sup>[19]</sup>. They have concluded that this occurrence is a part of Richter's transformation of the lymphoma. Jie Xu et al. had reported a T/HRLBCL of the thymus where the lymphocyte-rich background of T/HRLBCL can easily mimic lymphocyte predominant thymoma.<sup>[20]</sup>

Hemophagocytic lymphohistiocytosis (HLH) is an immune-mediated disorder characterized by fever, splenomegaly, and pancytopenia. Laboratory features include hypertriglyceridemia, hypofibrinogenemia, hemophagocytosis, low or absent NK-cell activity, hyperferritinemia, and an elevated soluble CD 25. The diagnosis is made with either the presence of molecular aberrations consistent with HLH, for example, pathologic mutations in PRF1, UNC13D, or STX11, or with fulfilment of five of eight clinical criteria outlined above. The pathophysiology of HLH involves the uncontrolled activation of T cells, histiocytes, and macrophages, resulting in an overproduction of inflammatory cytokines and consequent multiorgan damage<sup>[22]</sup>

Diagnosis is based on the revised HLH 2004 criteria, which include clinical, laboratory and histopathological findings. Some of the patients may not meet the entire criteria. It states that diagnosis can be established if there is a molecular diagnosis consistent with HLH or if the patient satisfies five out of eight criteria which include

fever, cytopenias (two or more lineages), splenomegaly, hypertriglyceridemia, hypofibrinogenemia, hemophagocytosis in bone marrow or spleen or lymph nodes, no evidence of malignancy, ferritin > 500 µg/L, low or absent NK cell activity, soluble CD25 > 2,400 U/mL, hemophagocytic activity in the bone marrow, other organs or CSF<sup>[29]</sup>. Our patient met five of the eight criteria required for the diagnosis of HLH

Till date, only six cases of HLH occurring in the setting of T/HRLBCL have been reported<sup>[23]</sup>. An interesting fact is that T/HRLBCL expresses the same cytokines such as tumor necrosis factor- $\alpha$ , interferon- $\gamma$ , and interleukin 6; that have been implicated in the pathogenesis of HLH<sup>[22]</sup>.

**Case reports in literature of hemophagocytic lymphohistiocytosis secondary to T cell histiocyte rich large B cell lymphoma.**

No	Age/Sex	Symptoms	Site	Immunophenotype	Treatment	Outcome	Reference
1	20/M	Jaundice, Malaise, Abdominal Pain, Feve	LN, Liver	CD3+ CD5+ CD7+ CD45+ T Cell Infiltrate Scattered Large CD20+ PAX5+ CD15- CD30- Alk-1- B-Cells	R-CHOP × 6 IT-MTX	Alive	[30]
2	52/M	Fever, DOE, Weight Loss	LN	Scattered Large CD20+ Cells CD3+ T Cells CD30- CD15- EBV-	R-CHOP × 8, IT-MTX, Cytarabine, MP	Recurrence At 10 M, Salvage Therapy	[31]
3	30/M	Fever, Jaundice, Weight Loss, ARF	LN, Lung	Large CD20+ CD15- CD30- B Cells CD3+ CD5+ CD7+ CD8+ TIA-1+Tcellscd68+Histiocytes	DA-R-EPOCH	Alive	[32]
4	30/F	Pruritus, Night Sweats, Fever, Weight Loss	LN, Liver	CD79a+Mib-1+ Large Cells	MOPP-ABV Then High Dose MTX, Vincristine And Etoposide, Then AHSCT	Alive	[33]
5	34/M	Fever, Abdominal Pain, Jaundice	BM	ND	ND	DOD	[34]
6	43/M	Fever	LN	Large Atypical Cell CD20+,PAX5+,BCL6+,MUM1+,EMA(Weak),Kappa(Weak)CD3+,CD2+,CD5+,CD7+,CD43+ T Cells	R-CHOP × 6	Alive	[35]
7	52/M	Fever	LN,BM	CD3+,CD20+(Large Cells),LCA+(Large Cells),PAX-5+(Large Cells-Weak),,BOB-1+(Large Cells),OCT2+,PD1a+,CD21+CD61+Megakaryocyte),CD30+( Large Cells),	R-CHOPX6	Alive	[CURRENT CASE]

AHSCT: autologous hematopoietic stem cell transplant; BM: bone marrow; DA-R-EPOCH: dose adjusted Rituximab, Etoposide, Prednisone, Vincristine (Oncovin), Cyclophosphamide, and Doxorubicin; DOE: dyspnea on exertion; DOD: died of disease; IT-MTX: intrathecal methotrexate; LN: lymph node; M: months; MOPP-ABV: mechlorethamine, vincristine, procarbazine, prednisone/doxorubicin bleomycin, and vincristine; MP: methylprednisolone; ND: not described; R-CHOP: Rituximab, Cyclophosphamide, Doxorubicin, Vincristine, and Prednisone.

T/HRLBCL is an aggressive B cell NHL and it should be treated as high grade large cell lymphoma [24]. CHOP (Cyclophosphamide, doxorubicin, vincristine and prednisolone) chemotherapy in combination with rituximab is used in T/HRLBCL treatment as it is used in all CD 20 positive nodal and extra nodal lymphoma. Response to the treatment and prognosis of cases with T/HRLBCL are similar to the DLBCL cases at the same stage [25]. Studies have shown complete response rate to CHOP-like therapy in the range of 56- 63% with 3- year and 5- year overall survival rates, estimated at 50-64% [26]. More than 90% of patients are detected in stage III or IV disease, and bone marrow involvement is more common (>50%). Such cases have a relatively poor prognosis, with 5 year survival rate of 20% [27]. Treatment options for refractory or recurrent disease include Alemtuzumab, a monoclonal antibody to the CD52 protein expressed on the surface of mature T cells and possibly NK cells [28].

### Conclusion

T-cell/Histiocyte-Rich Large B-cell Lymphoma is a recent clinic-pathological entity which needs more awareness among the clinicians in the current clinical practice. It is distinguished from diffuse large B-cell lymphoma by various clinical and pathologic features and is characterized by an aggressive behavior. HLH is a potentially fatal condition and when it is secondary to an

aggressive malignancy like T/HRLBCL, requires prompt suspicion, early diagnosis and initiation of treatment which could be life-saving. Treating the HLH is important for symptomatic control; however treating the primary disease remains the priority in the long-term in the management of these patients. T/HRLBCL is treated with standard chemotherapy (Rituximab- CHOP) and had resulted in favorable outcomes. Therefore, first-line treatment of T/HRLBCL with R-CHOP is recommended until we get further clinical evidences. Gene expression profiling will play a pivotal role in the near future to identify an individual's lymphoma targets, thereby leading to optimal combinations of standard care and enhanced patient outcomes.

### References

1. Shiyong Li, Constance A Griffin, Risa B Mann, Michael J Borowitz. Primary Cutaneous T-Cell—Rich B-Cell Lymphoma: Clinically Distinct from Its Nodal Counterpart? *Modern Pathology* 2001; 14:10-13.
2. Pitttaluga S, Elaine S, Jaffe. T-cell/histiocyte-rich B-cell lymphoma. *Haematologica*. 2010; 95:352-356.
3. Ramsay AD, Smith WJ, Isaacson PG. T-cell-rich B-cell lymphoma. *Am J Surg Pathol* 1988;12:433-443
4. Delabie J, Vandenberghe E, Kennes C et al. Histiocyte-rich B-cell lymphoma. A distinct clinicopathologic entity possibly related to lymphocyte predominant Hodgkin's disease, paragranuloma subtype. *Am J Surg Pathol* 1992;16:37-48
5. Shimodaira S, Hidaka E, Katsuyama T. Clonal identity of nodular lymphocyte-predominant Hodgkin's disease and T-cell-rich B-cell lymphoma. *N Engl J Med* 2000;343:1124-1125
6. T. Tousseyn and C. De Wolf-Peeters, "T cell/histiocyte-rich large B-cell lymphoma: an update on its biology and classification," *Virchows Archiv*, vol. 459, no. 6, pp. 557-563, 2011.

7. Armitage JO, Weisenburger DD. New approach to classifying non-Hodgkin's lymphomas: clinical features of the major histologic subtypes. Non-Hodgkin's Lymphoma Classification Project. *J Clin Oncol* 1998;**16**:2780–2795.
8. Bouabdallah R, Mounier N, Guettier C et al. T-cell/histiocyte-rich large B-cell lymphomas and classical diffuse large B-cell lymphomas have similar outcome after chemotherapy: a matched-control analysis. *J Clin Oncol* 2003;**21**:1271–1277.
9. Achten R, Verhoef G, Vanuytsel L et al. T-cell/histiocyte-rich large B-cell lymphoma: a distinct clinicopathologic entity. *J Clin Oncol* 2002;**20**:1269–1277.
10. Greer JP, Macon WR, Lamar RE et al. T-cell-rich B-cell lymphomas: diagnosis and response to therapy of 44 patients. *J Clin Oncol* 1995;**13**: 1742–1750.
11. Gatter KC, Warnke RA. Diffuse large B-cell lymphoma. In: Jaffe ES, Harris NL, Stein H et al., eds. *Tumours of Haematopoietic and Lymphoid Tissues*. Lyon: IARC Press, 2001:171–174.
12. Aki H, Tuzuner N, Ongoren S et al. T-cell-rich B-cell lymphoma: a clinicopathologic study of 21 cases and comparison with 43 cases of diffuse large B-cell lymphoma. *Leuk Res* 2004;**28**:229–236.
13. Lim MS, Beaty M, Sorbara L et al. T-cell/histiocyte-rich large B-cell lymphoma: a heterogeneous entity with derivation from germinal center B cells. *Am J Surg Pathol* 2002;**26**:1458–1466.
14. Gascoyne RD, Adomat SA, Krajewski S et al. Prognostic significance of Bcl-2 protein expression and *bcl-2* gene rearrangement in diffuse aggressive non-Hodgkin's lymphoma. *Blood* 1997;**90**:244–251.
15. Kramer MH, Hermans J, Wijburg E et al. Clinical relevance of BCL2, BCL6, and MYC rearrangements in diffuse large B-cell lymphoma. *Blood* 1998;**92**:3152–3162.
16. Hartmann S, Döring C, Jakobus C, Rengstl B, Newrzela S, [12]Tousseyn T, et al. Nodular lymphocyte predominant hodgkin lymphoma and T cell/histiocyte rich large B cell lymphoma - endpoints of a spectrum of one disease? *PLoS ONE*. 2013;8(11):e78812.
17. Pandure M, Karle R, Dongre S, Deshpande V. T-cell rich large B-cell lymphoma: a rare variant of diffuse large b cell lymphoma. *Annals of Pathology and Laboratory Medicine*. 2016;3(1):27-31.
18. Advani P, Starr J, Swaika A, Jiang L, Qiu Y, Li Z, et al. T-cell]histiocyte-rich large B-cell lymphoma presenting as a primary central nervous system lymphoma. *Rare Tumors*. 2015; 7(4):6084.
19. Türköz H, Polat N, Akin I, Özcan D. Micronodular T-cell/histiocyte-rich B-cell lymphoma of the spleen in a case of small lymphocytic lymphoma: A Richter's transformation. *Upsala Journal of Medical Sciences*. 2010;115(3):217-19.
20. Jie Xu, Xiaojun Wu, and Vishnu Reddy, T Cell/Histiocyte-Rich Large B Cell Lymphoma of the Thymus: A Diagnostic Pitfall. *Case Reports in Hematology* Volume 2016 (2016), Article ID 2942594
21. Brune V, Tiacci E, Pfeil I, Doring C, Eckerle S, van Noesel CJ, et al. Origin and pathogenesis of nodular lymphocyte-predominant Hodgkin lymphoma as revealed by global gene expression analysis. *J Exp Med*. 2008;205(10):2251-68.
22. M. Ramos-Casals, P. Brito-Zer'on, A. L'opez-Guillermo, M. A. Khamashta, and X. Bosch, "Adult haemophagocytic syndrome," *The Lancet*, vol. 383, no. 9927, pp. 1503–1516, 2014.
23. E.M.Mahtat,M. Zine,M. Allaoui et al., "Hemophagocytic lymphohistiocytosis complicating a T-cell rich B-cell lymphoma," *BMC Hematology*, vol. 16, no. 1, article 28, 2016.

24. Shahabuddin D, Raghuveer CV. Reed-Sternberg-like cells in T- cellrich B-cell lymphoma: a diagnostic dilemma. *Indian Journal of PatholMicrobiol* 2003; 46(1):55-56.
25. Koksal AR, Alkin H, Ergun M, Boga S, Mehmet Bayram, Canan Alkim et.al. First case of T-cell/histiocyte-rich B-cell lymphoma presenting with duodenal obstruction. *Libyan Journal Med* 2013;8:22955
26. Jeremy S. Abramson. T-Cell/Histiocyte Rich B-Cell Lymphoma: Biology, Diagnosis and Management. *The Oncologist* 2006; 11(4):384-392.
27. Jhon K C Chan. Tumours of Lymphoreticularsystem. Christopher D. M. Flecher. Tumours of lymphoreticular system .Diagnostic Histopathology of Tumors. Third Edition. Vol 2.Place- Philadelphia. Published by Churchill Livingstone ELSVIER.2007: page 1204.
28. S. Weitzman, "Approach to hemophagocytic syndromes," *Hematology/The Education Program of the American Society of Hematology*, vol. 2011, no. 1, pp. 178–183, 2011.
29. Bode SF, Lehmborg K, Maul-Pavicic A, Vraetz T, Janka G, Stadt UZ, Ehl S. Recent advances in the diagnosis and treatment of hemophagocytic lymphohistiocytosis. *Arthritis Res Ther*. 2012;14(3):213.
30. M. Mehta, J. Wang, R. McHenry, and S. Zucker, "T-cell/histiocyte- rich large B-cell lymphoma masquerading as autoimmune hepatitis with clinical features of hemophagocytic lymphohistiocytosis," *Journal of Gastrointestinal & Digestive System*, vol. 5, article 3, 2015.
31. E.M.Mahtat,M. Zine,M. Allaoui et al., "Hemophagocytic lymphohistiocytosis complicating a T-cell rich B-cell lymphoma," *BMC Hematology*, vol. 16, no. 1, article 28, 2016.
32. K. Devitt, J. Cerny, B. Switzer et al., "Hemophagocytic lymphohistiocytosis secondary to T-cell/histiocyte-rich large B-cell lymphoma," *Leukemia Research Reports*, vol. 3, no. 2, pp. 42–45, 2015.
33. M. Mitterer, N. Pescosta, C. Mc Quain et al., "Epstein-Barr virus related hemophagocytic syndrome in a T-cell rich B- cell lymphoma," *Annals of Oncology*, vol. 10,no. 2, pp. 231–234, 1999.
34. O. S. Aljitiawi and J. M. Boone, "Lymphoma-associated hemophagocytic lymphohistiocytosis," *Blood*, vol. 120, no. 5, article 932, 2012.
35. Uroosa Ibrahim,1 Gwenalyn Garcia,1 Amina Saqib,2 Shafinaz Hussein,3 and Qun Dai1, "T Cell Histiocyte Rich Large B Cell Lymphoma Presenting as Hemophagocytic Lymphohistiocytosis: An Uncommon Presentation of a Rare Disease," *Case Reports in Oncological Medicine*" Volume 2017, Article ID 6428461