



Hereditary hemorrhagic telangiectasia: A rare cause of severe anemia

Dr Ravi Prakash, PG Student Medicine S.M.S Medical College, Jaipur

Dr Pradeep Mital, Sr Professor and Unit head Medicine S.M.S Medical College, Jaipur

Dr Sujata Agarwal, Associate Professor Medicine S.M.S Medical College, Jaipur

Dr Aradhana Singh, Associate Professor Medicine S.M.S Medical College, Jaipur

Dr Vinay Kumar Meena, Assistant Professor Medicine S.M.S Medical College, Jaipur

Corresponding Author: Dr Pradeep Mital, Sr Professor and Unit head Medicine S.M.S Medical College, Jaipur , India

Type of Publication: Case Report

Conflicts of Interest: Nil

Abstract

Hereditary hemorrhagic telangiectasia (HHT) is an uncommon autosomal dominant inherited multisystem disorder in which abnormal arteriovenous communications (telangiectasias) develops which characteristically affects small blood vessels in the skin, mucous membranes, gastrointestinal tract & organs such as liver, lungs and brain causing vascular dysplasia and tendency for bleeding. This is a rare condition which often goes unrecognized & misdiagnosed because of its non specific symptoms which vary among affected population. HHT, though usually presents as recurrent epistaxis, gastrointestinal bleeding & arteriovenous malformations, iron deficiency anemia is found in few patients of HHT and is usually mild. Concomitant severe anemia in HHT is rarely seen and is found in elderly. This article presents a case of a 30 year old man presented with recurrent epistaxis since childhood. Investigating results showed multiple telangiectasias in gastrointestinal tract, hemangiomas in liver & arteriovenous malformations (AVMs) in lungs. Based on Curacao criteria, it was diagnosed as severe iron deficiency anemia with hereditary hemorrhagic telangiectasia.

Keywords: Hereditary hemorrhagic telangiectasia, iron deficiency anemia, arteriovenous malformation, epistaxis

Introduction

Hereditary hemorrhagic telangiectasia also known as Osler Weber Rendu syndrome is a rare (1in 5000-8000) autosomal dominant genetic disorder, despite the fact that about 20 % cases are unaware of a positive family history¹. It leads to abnormal blood vessels formation in skin, mucous membranes & visceral organs due to defective angiogenesis. Defective angiogenesis causes alteration in elastic & muscle layer of vessel walls, making them more prone to spontaneous rupture & injuries². HHT is attributed to aberrant signaling TGFβ1 receptor involved in angiogenesis. HHT 1 is caused by mutation gene ENG encoding endoglin on chromosome 9q and HHT 2 is caused by mutation in gene ALK-1 (Activin Receptor like Kinase-1) on chromosome 12-13. HHT1 & 2 accounts for approximately 85% of cases³.

Clinical manifestations

Clinical manifestations of HHT are variable, recurrent epistaxis is most common presenting symptom seen in about 90 % of patients. Mucocutaneous telangiectasia are seen in 80 % of patients with involvement of skin lip, nail

bed or oral mucosa³. Half of patients manifest cutaneous lesions by age of 30 years. Pulmonary AVMs seen in 40-50% of cases, large multiple AVMs may result in dyspnea, fatigue, cyanosis, clubbing & polycythemia. Hepatic AVMs occur in 30-40 % patients of HHT, hepatic AVMs can lead to right upper quadrant pain, jaundice, hepatomegaly, high output heart failure, portal hypertension, encephalopathy & liver failure^{4,5,6}. Cerebral AVMs seen in 10-20 % HHT patients may lead to stroke, brain abscesses or intracerebral hematoma with focal neurological signs. Spinal AVMs are seen in 1% cases⁶. GI telangiectatic lesions most commonly involved mucous surface of stomach & small bowel. GI bleeding develops in 15-20 % cases of HHT².

Diagnosis of HHT

The diagnostic Curacao criteria were developed based on four criteria of spontaneous recurrent nosebleeds, mucocutaneous telangiectasia (multiple & at lips, oral cavity, fingers, nose) visceral involvement (Gastrointestinal telangiectasia, pulmonary, hepatic, cerebral or spinal AVM) and an affected first degree relative, to allow a high degree of suspicion without overdiagnosis⁷. The diagnosis of HHT is definite when three criteria are present, suspected if two criteria are present, most commonly family history and nose bleeds, or unlikely when only one criterion is present.

Management of HHT

Treatment of HHT is largely conservative. Anemia may require multiple blood transfusions & iron supplementation. Topical as well as systemic estrogen therapy reduces mucosal bleeding. Nose bleeds often require Nd:Yag or Argon laser treatment⁸ or local injection of sclerosing agents. Antiangiogenesis agents like bevacizumab & thalidomide have also proven to be effective in reducing mucosal bleeding⁹. Treatment options of GI bleeding includes endoscopic Argon

Plasma Coagulation (APC) & Nd-YAG laser ablation of mucosal telangiectatic lesions. Management options for skin lesions include long pulsed Nd-YAG laser ablation & skin grafting. Pulmonary hepatic & cerebral AVMs needs embolisation of the feeding vessels by clipping or coiling. Liver transplantation is indicated in cardiac failure, biliary necrosis & severe portal hypertension¹⁰. Aspirin & anticoagulant agents are contraindicated in patients with active bleeding^{2,6}.

Anemia in HHT can be due to recurrent epistaxis or chronic gastrointestinal bleeding and is usually mild. However concomitant severe anemia is a rare presentation of Hereditary Hemorrhagic telangiectasia, which needs high index of suspicion for diagnosis. This rare condition often goes unrecognized & misdiagnosed because of its non specific & variable presentation among affected population^{2,4,11}. Here we present a case report where a thirty years old male with Hereditary Hemorrhagic telangiectasia presented with severe anemia.

Case Report

A 30 year, chronic smoker, male, presented with easy fatigability for one year, generalized weakness for 6-8 months & dizziness for last 1 month and skin lesions which first appeared on nail bed of both hands, gradually progressing to finger, tongue, oral cavity, face, trunk & lower abdomen. Significant past history was recurrent episodes of epistaxis since age of 9 years, spontaneous in nature, lasting for 3-5 minutes only, it had no seasonal or diurnal variation. There was no history of hemarthrosis and similar problem in any other member of his family.

On examination patient had sign & symptom of anemia, his nasal mucosa was inflamed. Skin lesions were reddish purple in colour, slightly elevated, sharply demarcated maculopapular & punctate, size ranging from 0.25 to 3.5 mm, blanchable & non tender present on nail bed of both

hands, finger, tongue, oral cavity, face, trunk & lower abdomen (Fig 1&2).

Patients haemogram suggested severe iron deficiency anemia (Table-1). Stool was negative for occult blood. Chest X Ray showed a Nodular prominence over right hilar region(Fig.3). Differentials for this patient were hereditary hemorrhagic telangiectasia, hemophilia & Von willebrand disease. Hemophilia& von willebrand disease were excluded due to no muscle joint hematoma or swelling, no sign of easy bruising & no family history of bleeding disorder.

Patient was further investigated to find other possible causes of anemia

Upper GI endoscopy revealed multiple mucosal telangiectasias from oral cavity up to second part of duodenum (Fig-4), which were not bleeding at the time of study. Lower GI mucosa was found normal on colonoscopy. Triple phase CT abdomen revealed two hepatic hemangiomas (Fig-5), CT angiography of chest showed small AVM in lower lobe of right lung (Fig-6). No similar lesions detected in brain.

So in the view of recurrent epistaxis, mucocutaneous telangiectasia & visceral lesions a diagnosis of HHT was made based on Curacao criteria.

Patient was treated with 5 units of PRC transfusion, injection iron sucrose, oral haematinics & Hormone Replacement Therapy (Tab Tamoxifene 20 mg OD).With this patient's general condition improved significantly. Patient has been planned for ablation of GI lesions by endoscopic Argon plasma coagulation & intervention embolization for pulmonary AVM.

Discussion:

Association of severe anemia, like the one present in our patient of HHT is highly unusual. After extensive internet search only 26 cases reports of severe anemia due to HHT were found till date^{2,4,11,12,13}. Previous studies have shown

that most common cause of severe anemia in patients of HHT were chronic gastrointestinal bleeding in 70% followed by epistaxis in 25%, both of which are evident in this reported case¹². Iron deficiency anemia found in HHT is usually mild and if severe is found in elderly¹⁴. Our reported case is also unique in the sense that this patient develops severe anemia at the age of 30 years probably due to recurrent epistaxis & GI bleeding. Patients with HHT presents with normal hemostasis and normal platelet function; hence recurrent bleeding is related to telangiectasia. Number of telangiectasia decides the severity of anemia.

Conclusion: HHT is rare disease. Further it rarely causes severe anemia & therefore is not included in differential diagnosis of anemia. Severe anemia and negative family history make the disease more rarer as in our case. HHT should be suspected in patients with early onset recurrent nasal or GI bleeding with normal coagulation profile. Though HHT is a rare disease, we need to have very high index of suspicion to establish its relation to iron deficiency anemia, this can be recognized in most patients due to its classic presentation and diligent general physical examination.

References

1. **Dakeishi M**, Shioya T, Wada Y, et al. Genetic epidemiology of hereditary haemorrhagic telangiectasia in a local community in the northern part of Japan. *Hum Mutat*2002;**19**:140–8.
2. **Deshpande P**, Bhat S, Karmarkar A. Hereditary Haemorrhagic Telangiectasia - A of Severe Anaemia. *Journal of the association of physicians of India* 2014 (62)48-51.
3. **Yokoo K**, Yamadaa G, Chibab H, Ishikawac A, Morisakid H,Saijob H,et,al. A new ENG mutation in a Japanese family with hereditary hemorrhagictelangiectasia and pulmonary

- arteriovenous malformations. *Respiratory Medicine Case Reports* 25 (2018) 73–77.
- Vesna Supak, Lidija Bilic-Zulle et al. Case report of hereditary hemorrhagic telangiectasia with severe anemia. *Biochemia Medica* 2008;18:106-14
 - BKin MM, Massoud E. Hereditary hemorrhagic telangiectasia: an under-recognized but potentially serious condition. *DMJ* 2016; 42(2):19-21.
 - Olitsky SE. Hereditary Hemorrhagic Telangiectasia: Diagnosis and Management. *American Family Physician* 2010;1:82 (7):785-790.
 - Shovlin CL, Guttmacher AE, Buscarini E, et al. Diagnostic criteria for hereditary haemorrhagic telangiectasia (Rendu-Osler-Weber syndrome). *Am J Med Genet* 2000;91:66–7.
 - Shah RK, Dhingra JK, Shapshay SM. Hereditary hemorrhagic telangiectasia: a review of 76 cases. *Laryngoscope*. 2002 May. 112(5):767-73.
 - Franchini M, Frattini F, Crestani S, Bonfanti C. Novel treatments for epistaxis in hereditary hemorrhagic telangiectasia: a systematic review of the clinical experience with thalidomide. *J Thromb Thrombolysis*. 2013 Oct. 36(3):355-7.
 - Lerut J, Orlando G, Adam R, et al. Liver transplantation for hereditary hemorrhagic telangiectasia: Report of the European liver transplant registry. *Ann Surg*. 2006 Dec. 244(6):854-62; discussion 862-4.
 - Kiyeng JC, Siika A, Koech Cand Bloomfield GS. Kiyeng. Definite hereditary hemorrhagic telangiectasia in a 60-year-old black Kenyan woman: a case report. *Journal of Medical Case Reports* 2016 (10):126:1-4.
 - Santos JWA, Dalcin TC, Neves KR, Mann KC, Pretto GLN & Bertolazi AN. Hereditary hemorrhagic telangiectasia: a rare cause of severe anemia. *J. bras. pneumol.* 2007, (33)1:109-112.
 - Gebeyehu R, Lall T, Iyasu G, Fadhil A, Teferi M. A Case of Hereditary Hemorrhagic Telangiectasia with Severe Anemia [abstract]. *Journal of Hospital Medicine*. 2015; 10 (suppl 2). <https://www.shmabstracts.com/abstract/a-case-of-hereditary-hemorrhagic-telangiectasia-with-severe-anemia/>. Accessed August 27, 2018.
 - Sengupta A, Saha k, Jash D, Banerjee SN. Dyspnea with anemia turned out to be a case of hereditary hemorrhagic telangiectasia. *Asian Journal of Transfusion Science* 2013 :7(1):75-78.

Figures

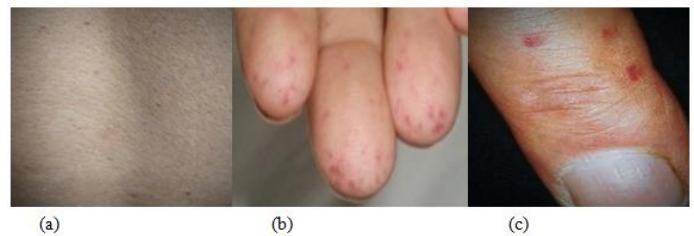


Figure 1: Telangiectatic lesions over (a) back (b & c) fingers

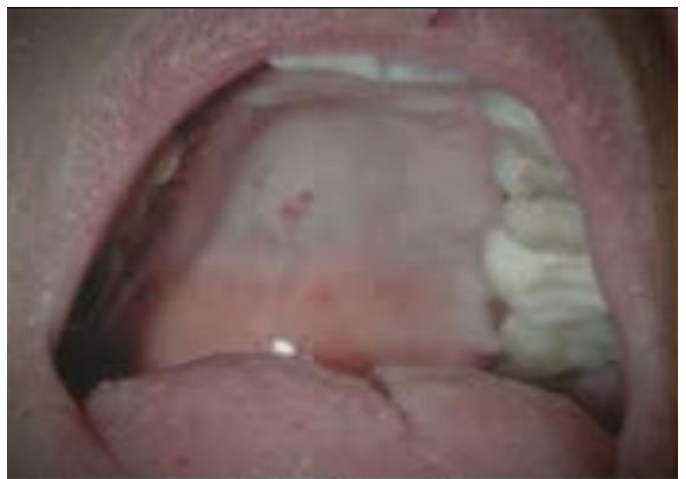

Figure 2 : Telangiectatic lesions over oral mucosa

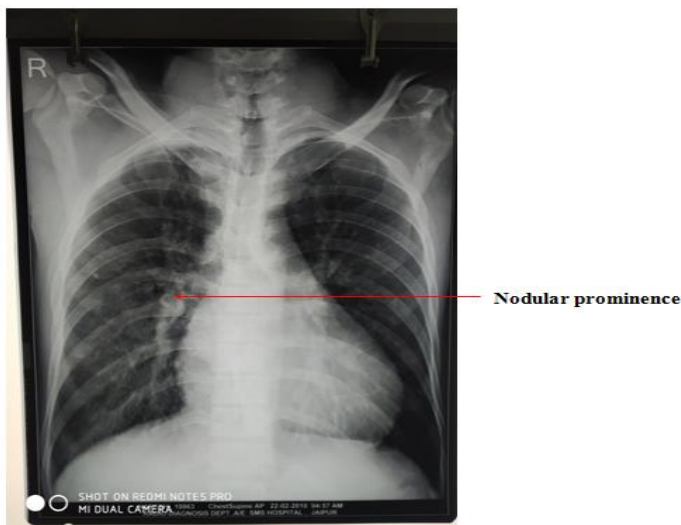


Figure 3: Chest X ray PA view

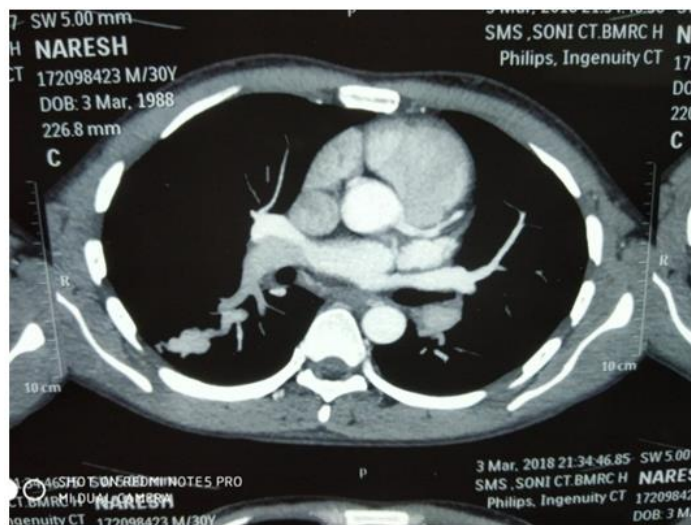


Figure 6: CT chest angiography showing right pulmonary arteriovenous malformations

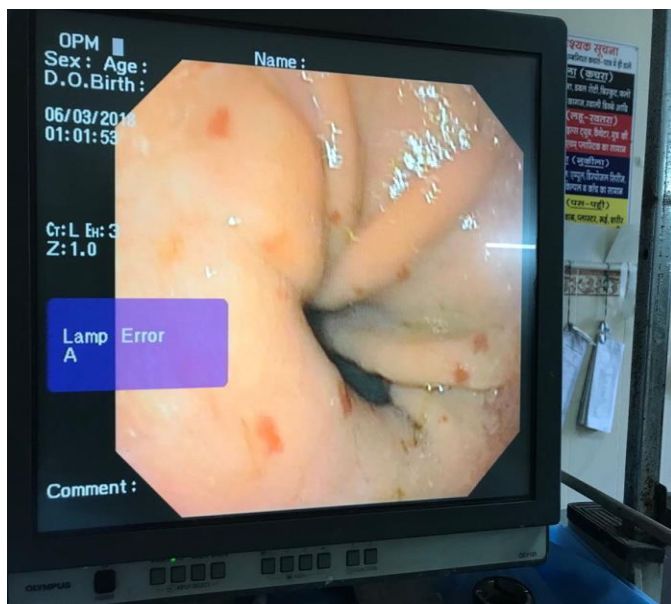

Figure 4: Telangiectasias on esophageal mucosa

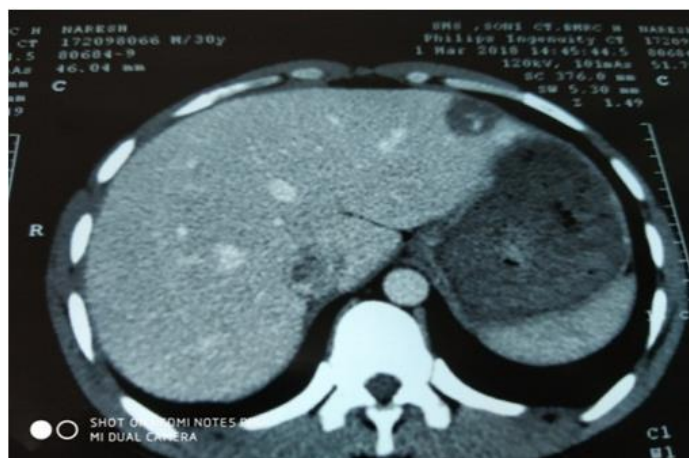

Figure 5: Triple phase CT abdomen showing hepatic hemangioma.

Table 1: Investigations

Investigations	Value
Hb	4.7g/dl (14-18 g/dl)
TLC	8.8*1000/mm ³ (4.3-10.0*1000/mm ³)
Platelets	2.96 (1.4-4.4 lac/mm ³)
MCV	67.2 (70-99 fl)
MCH	18.1 (26-32 pg)
MCHC	27 (32-36 g/dl)
Ferritin	14.4 ng/ml (22-322 pg/ml)
S. Iron	12 ug/dl (40-150 ug/dl)
TIBC	640 (255-450ug/dl)
Vitamin B ₁₂	457 (211-911pg/ml)
Folate	8.5 (3-17 ng/ml)
BT	2.27 (2-5 min)
CT	4.29 (3-5 min)
Stool for occult blood	negative