

Morphometric Study of Femoral Artery and Profunda Femoris Artery in Femoral Triangle in Adult Human Cadavers

¹Nisha Shyamsundar Pareek, ²Dr. Nitin Radhakishan Mudiraj, ³Dr. Manisha Randhir Dhobale

¹Nisha Shyamsundar Pareek, Dept. of Anatomy, Bharati Vidyapeeth (Deemed to be University) Medical college and Hospital Sangli. State – Maharashtra, India

²Dr. Nitin Radhakishan Mudiraj, Dept. of Anatomy, Bharati Vidyapeeth (Deemed to be University) Medical college and Hospital Sangli. State – Maharashtra, India

³Dr. Manisha Randhir Dhobale, Dept. of Anatomy, Bharati Vidyapeeth (Deemed to be University) Medical college and Hospital Sangli. State – Maharashtra, India

Corresponding Author: Dr. Nitin R Mudiraj, Department of Anatomy, Bharati Vidyapeeth (Deemed to be University) Medical College and Hospital Sangli, India

Type of Publication: Original Research Paper

Conflicts of Interest: Nil

Abstract

Introduction: The pulsation of femoral artery can be felt at its origin, where the vessels can be compressed against the superior ramus of the pubis or the head of the femur. Like the carotid pulse, the femoral pulse is of value in assessing whether there is any significant cardiac output in cases of circulatory collapse. It is common site for radiological catheter insertion and for arterial puncture for blood gas analysis.

Materials and Methods: Hundred specimens of lower limb from 50 adult human cadavers fixed in 10% formalin was collected from Bharati Vidyapeeth (Deemed to be University) Medical College and Hospital Sangli and Government Medical Collage Miraj. Femoral artery and its branches were dissected meticulously.

Result: Commonest site of origin of profunda femoris artery was from the lateral aspect (35 cases) of femoral artery.

Conclusion: The femoral artery is quite superficial in the femoral triangle. It can be easily exposed for ligation, i.e. tying, or for passing a cannula or a thick needle. Catheters are passed upwards till the heart for certain minor operation.

Keywords: Femoral artery, profunda femoris artery, mid-inguinal point

Introduction

The femoral artery is a continuation of the external iliac artery. It begins behind the inguinal ligament, midway between the anterior superior iliac spine and the pubic symphysis.

The profunda femoris artery (deep femoral artery) is a large branch that arises laterally from the femoral artery about 3.5 cm distal to the inguinal ligament. The profunda is the main supply to the adductor, extensor and flexor muscles, and also anastomoses with the internal and

external iliac arteries above and with the popliteal artery below.¹

Femoral artery in lower extremity and radial artery in upper extremity are preferred vessels for various surgical procedures. Femoral angiography is the main line for the investigations in the peripheral occlusive arterial disease and in diagnosis of suspected congenital anomalies.²

The development of the vasculature in the lower limb precedes the morphological and molecular changes that occur in the limb mesenchyme, hence vascular variations are more of a rule than an exception.³

Hence present study has been undertaken to contribute to the ever evolving vast knowledge of normal anatomy of femoral artery and profunda femoris artery in femoral triangle.

Materials & Methods

After an ethical approval (Letter No-BVDU/MCH/3120/2017-18), the descriptive and observational study was carried out from 2016 to 2018 . The study was carried out on 50 (100 lower limbs) formalin fixed human cadaver’s from department of Anatomy of Bharati Vidyapeeth (Deemed to be University) Medical College and Hospital Sangli and Government Medical Collage Miraj. Front of thigh was dissected carefully according to Cunningham’s practical book, 15th edition.⁴ The skin and superficial fascia was incised and reflected from the front of thigh. The superficial inguinal lymph nodes were cleaned and the fascia lata was removed to expose the femoral triangle. Inguinal ligament was identified. Femoral sheath was split to expose the femoral contents. Following parameters were noted

- Relation of profunda femoris artery at its origin to the femoral artery was noted.

- Distance of origin of profunda femoris artery from the midinguinal point measured by thread and scale in cm
- External diameter of femoral artery at its origin as well as its termination was measured with the help of digital vernier caliper in mm
- External diameter of profunda femoris artery at its origin from the femoral artery was measured with the help of digital vernier caliper in mm.
- Representative specimen were photographed with Canon digital camera.
- The data was analysed with the help of Microsoft word excel software.

Result

The morphometric study of femoral artery and profunda femoris artery in femoral triangle carried out in 100 lower limbs belonging to 50 cadavers. The following observations were noted.

Table 1 : Relation of Profunda Femoris Artery at its Origin to the Femoral Artery

Site of Origin	Right %	Left %	Total
Posterolateral aspect	14 28%	13 26%	27
Posterior aspect	16 32%	17 34%	33
Lateral aspect	18 36%	17 34%	35
Medial aspect	02 4%	03 6%	05
Total	50 100%	50 100%	100

Origin of profunda femoris artery from lateral aspect of femoral artery was most common while that from medial aspect was least common in present study. In two cases profunda femoris artery was arising as a common trunk along with lateral and medial circumflex femoral artery (trifurcation) from posterior aspect of femoral artery.

Table 2 : Distance of Origin of Pro-funda Femoris Artery From the Midinguinal Point

Range (cm)	Right	%	Left	%
0 – 1.0	03	6	04	8
1.1 – 2.0	09	18	15	30
2.1 – 3.0	15	30	15	30
3.1- 4.0	18	36	09	18
4.1 – 5.0	03	6	06	12
5.1 – 6.0	02	4	01	2

The average distance of origin of profunda femoris artery from midinguinal point was 2.9 cm on right side and 2.5 cm on left side.

Table 3 : High Origin of Profunda Femoris Artery From the Midinguinal Point (cm)

Sr. no.	Distance of origin of profunda femoris artery from the midinguinal point (cm)	
	Right	Left
1	-	0.7
2	-	0.6
3	0.7	0.7

4	0.4	0.5
5	1.0	-

High origin of profunda femoris artery was found in total 7 cases, 3 on right side and 4 on left side. It was bilateral in 2 cadavers and unilateral in remaining.

Table 4 : Mean External Diameter of Femoral Artery at its Origin

Side	No. of specimen	Mean (mm)	SD	Range (mm)
Right	50	8.2	1.68	4.0-11.3
Left	50	8.4	1.50	3.5-13.5

Table 5 : Mean External Diameter of Femoral Artery at its Termination (at Hiatus Magnus)

Side	No. of specimen	Mean (mm)	SD	Range (mm)
Right	50	6.7	1.59	3.0-10.3
Left	50	6.9	1.48	3.4-9.8

Table 6 : Mean External Diameter of Profunda Femoris Artery Near its Origin From the Femoral Artery

Side	No. of specimen	Mean (mm)	SD	Range (mm)
Right	50	5.4	1.05	4.2-8.6
Left	50	5.3	1.25	2.3-8.1

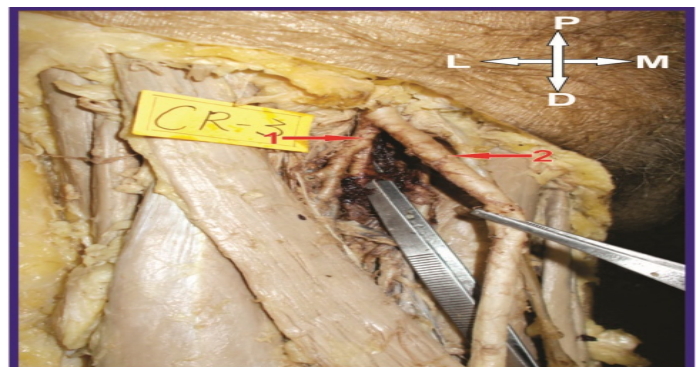

Fig. 1 : Picture of dissected specimen showing the PFA (1) arising from the posterolateral aspect of FA (2) in a right lower limb.

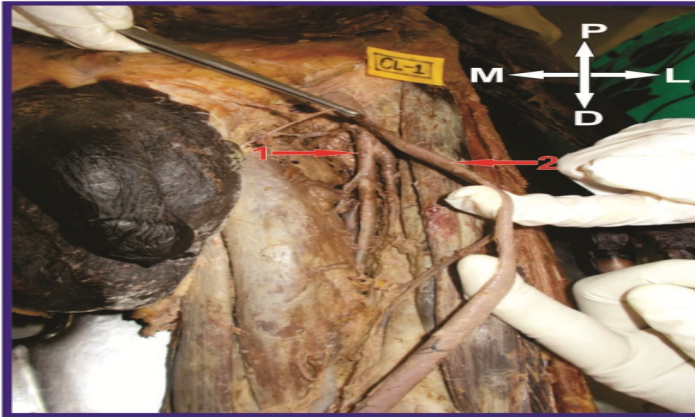


Fig. 2 : Picture of dissected specimen showing the PFA (1) arising from the posterior aspect of FA (2) in a left lower limb.

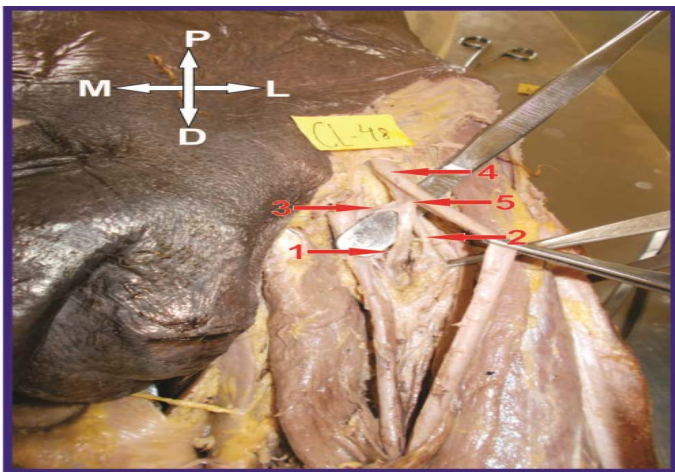


Fig. 3 : Picture of dissected specimen showing the PFA (1), LCFA (2) & MCFA (3) arising from the posterolateral aspect of FA (4) as a common stem (5) – trifurcation in a left lower limb.

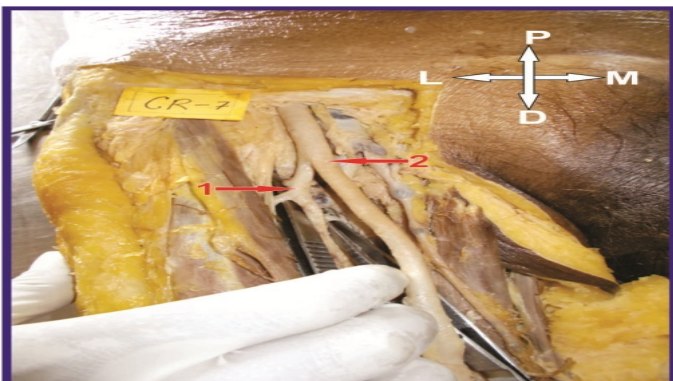


Fig. 4 : Picture of dissected specimen showing the PFA (1) arising from the lateral aspect of FA (2) in a right lower limb.




Fig. 5 : Picture of dissected specimen showing the PFA (1) arising from the medial aspect of FA (2) in a left lower limb.

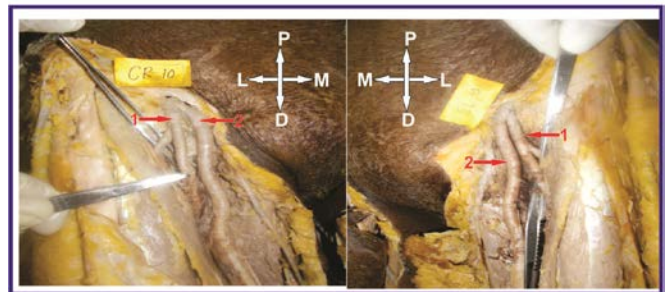


Fig. 6 : Picture of dissected specimen showing the PFA (1) arising from the lateral aspect of FA (2) at higher level in lower limbs of both sides.

Discussion

Bilateral weak femoral pulse compared to the radial pulse is indicative of coarctation (narrowing) of arch of aorta. The femoral pulse may be reduced or obliterated by atherosclerotic changes or by blockage of common iliac or external iliac artery or arteries by an embolus. Sudden occlusion or block in the femoral artery usually occurs due to emboli from the heart (myocardial infarction or thrombi in the left atrium in mitral stenosis) or due to

traumatic injury to the artery as in the fracture of femur or due to diabetes.

The femoral artery is relatively superficial in position in the thigh; it is easy to approach. The artery is used for various procedure like to inject radiopaque dye in the arteries of abdomen (aortic angiography, celiac artery angiography, superior and inferior mesenteric angiography, etc.). The catheter is introduced through the femoral artery. It is also a favored vessel for coronary angiography or for coronary angioplasty (retrograde catheterization).⁵

Aghera B⁶ had found the profunda femoris artery arising from posterolateral aspect in 47 limbs (46.07%), posterior aspect in 24 limbs (23.52%), lateral aspect in 20 limbs (19.60%) and medial aspect in 11 limbs (10.78%).

Ahire V⁷ et al, found the high origin of profunda femoris artery in 3 cases (5.8%) on the right side and in 4 cases (7.8%) on the left side. This incidence was similar to present study.

The advantage of such a high origin of profunda femoris artery is that it can be used for catheterization and further investigation of any arterial system of the body.³

Suthar K⁸ et al, reported the average distance of origin of profunda femoris artery from midinguinal point was 4.7 cm on right side and 4.4 cm on left side which was slightly higher than present study.

This distance is very important while performing cannulation of femoral artery, so that the profunda femoris artery is not endangered.⁹

The mean external diameter of profunda femoris artery recorded by Verma R¹⁰ et al at its origin was 6.8 mm on right side and 6.5 mm on left side was higher than present study.

Conclusion

A thorough knowledge of the normal anatomy and variations of profunda femoris artery and its circumflex branches is not only of paramount surgical importance during vascular diagnostic interventional procedures and surgeries but also helps in reducing the chances of intra-operative secondary haemorrhage and post-operative complications.³

Abbreviations

FA	- Femoral Artery
PFA	- Profunda Femoris Artery
mm	- Millimeter
cm	- Centimeter
SD	- Standard Deviation
CR (in photograph)	- Cadaver Right
CL (in photograph)	- Cadaver Left
P (in photograph)	- Proximal
D (in photograph)	- Distal
M (in photograph)	- Medial
L (in photograph)	- Lateral

References

1. Standring S. Pelvic girdle, gluteal region and hip joint. In : Gray's Anatomy, The anatomical basis of clinical practice. 40th edition Elsevier Churchill Livingstone, 2008, P - 1378-1381.
2. Dhamne V M, Sabnis A S. Origin of deep femoral artery and its anatomical variations. Indian Journal of Research. 2016; 5(11):69-71.
3. Daksha D P, Kubavat D M, Rathod S P, Pateld M M, Singel T C. A study of variations in the origin of profunda femoris artery and its circumflex branches. Int J Biol Med Res. 2011; 2(4):1084-1089.
4. Romanes, G.J. The hip and thigh- upper limb and lower limb- In : Cunningham's Manual of Practical

Anatomy vol.1. 15th edition Oxford University press 1986, P- 125-141.

5. Kulkarni N. Medial compartment of thigh. In : Clinical Anatomy for Student 1st edition 2007, P- 818.

6. Aghera B R, Sujath K, Taqdees F. Morphological study of origin of profunda femoris artery in human cadavers. Int J Anat Res. 2015; 3(3):1376-80.

7. Ahire V P, Rajgopal L. A study of profunda femoris artery in cadavers. Int J Cur Res Rev. 2014; 6(24):41-46.

8. Suthar K, Patil D, Mehta C, Patel V, Prajapati B, Bhatt C. Cadaveric study : Morphological study of branches of femoral artery in front of thigh. CIB Tech Journal of Surgery. 2013; 2(2):16-22.

9. Anjankar V P, Panshewdikar P N, Thakre G, Mane U, Tekale V. Morphological study on branching pattern of femoral artery: A cadaveric study. Asian Journal of Biomedical and Pharmaceutical Sciences.2014; 4(28):34-38.

10. Verma R K, Kumar A P, Rani A, Kumar N, Rani A. Variations in the origin of profunda femoris and circumflex femoral arteries : A cadaveric study. Indian journal of Clinical Anatomy and Physiology. 2016; 3(4):478-481.