

Cytomorphological Spectrum of Lymph Node Lesions Using Fine Needle Aspiration Cytology in Tertiary Care Centre

Naik Reena¹, Chawda Hanish K², Minj Manoj K³

¹Naik Reena, MBBS, DNB, Pathology, Assistant professor in Pathology, Govt Medical College (LSLAMMC), Raigarh, Chhattishgarh.

²Chawda Hanish K, MD, Pathology, Assistant professor in Pathology, Govt Medical College (LSLAMMC), Raigarh, Chhattishgarh.

³Minj Manoj K, MD, Pathology, Prof. and HOD, Dept of pathology, Govt Medical College (LSLAMMC), Raigarh, Chhattishgarh.

Corresponding Author: Dr. Hanish kumar chawda, Assistant Professor, Dept of Pathology, Govt Medical College, Raigarh, Chhattisgarh

Type of Publication: Original Research Paper

Conflicts of Interest: Nil

Abstract

Background: Fine Needle Aspiration Cytology (FNAC) is a simple and rapid diagnostic technique. Lymphadenopathy is one of the commonly encountered clinical Problems which has multitude of causes.

Objectives: To determine the pattern of disease affecting lymph nodes in this study region.

Methods: It was a retrospective study conducted in Department in Pathology of a newly set up tertiary care institution. The record-based data of 2 years was collected. The sample were then subjected to FNAC based on availability of resources. IBM SPSS 22 was used for analysis.

Results: The study was female preponderance with most of the patients comes under the group of 19-45 years. The criteria by which a diagnosis of reactive hyperplasia was established included high cell density, polymorphic patterns of cells and considerable number of tingible bodies macrophages. most common lymph node involved was cervical (72%) followed by

supraclavicular (7%) and other sites.

Cytomorphological feature of tuberculosis as seen epithelioid granuloma with necrosis for 39% of cases.

Conclusion: FNAC is useful and reliable in diagnosing neoplastic and non- neoplastic lesions of lymph nodes.

Keywords: FNAC, Tuberculosis, Metastasis, lymphadenitis, carcinoma.

Introduction

Lymphadenopathy is one of the commonly encountered clinical Problems which has multitude of causes. Fine needle aspiration cytology (FNAC) has become an important adjunct to the study of peripheral lymphadenopathy, as a rapid, reliable and inexpensive method of making a diagnosis and it is painless interventional procedure does not need anaesthesia, so it is widely acceptable in children and adults. There is no absolute contraindication of FNAC of lymph node. It is particularly relevant in developing and industrial countries like India where facilities for surgical biopsy are scarce. Lymphadenopathy is a commonly

encountered clinical problems which has multitude of causes varying from non-neoplastic to neoplastic conditions like inflammation, infection, primary or metastatic tumours.¹ Fine needle aspiration cytology (FNAC) has an important diagnostic role in the evaluation of peripheral lymphadenopathy and helps in deciding the appropriate management.² Tuberculous lymphadenitis is one of the most common causes of lymph node enlargement in developing countries.¹ FNAC plays an important role in diagnosing tuberculous lymph nodes and prevents unnecessary surgery. Treatment of tuberculosis can be straightaway started after FNAC diagnosis by correlation with clinical findings and other investigations. It is very simple, reliable, cost effective and safe alternative to excision biopsy.³ In our study, we have studied all peripherally enlarged lymph nodes with varied aetiologies by FNAC in patients of all age and sex to determine the pattern of disease affecting lymph nodes in our region.

Materials and Methods

Study Area- Department of Pathology at a newly develop Tertiary Care Centre, Raigarh

Study Design- Retrospective study

Study Population- Cytological Smears of suspected Cases

Study Duration: data from January 2015 to December 2016 (2 years) was gathered.

Sampling Technique: Purposive sampling technique

Sample size- A total of 208 cases of lymphadenopathy of varied aetiologies was considered.

Consent Type: Informed consent

Ethical Approval: Study was approved by Institutional Ethical Committee.

Methodology: All the samples which were subjected to laboratory were included in the study. Patients who

visited the OPD of our hospital, with complaints of superficial lymphadenopathy were sent for FNAC for proper diagnosis. informed consent was taken from the patients or guardian. FNAC was performed using 21-22-gauge needle attached to 10ml syringe. In each procedure, an average of 3 to 4 passes is usually performed and aspirated materials smeared into 2-3 slides. Slides were stained with giemsa stain and using D.P.X mountant and were prepared for cytological examination. we have done ZN Stain in all the suspected cases of tuberculosis either clinically or cytomorphologically. The reporting was done by experienced cytologists and the data of reported cases over past two years (2015-2017) were collected.

Statistical Analysis- The data were retrieved, compiled, summarized and statistically analyzed by frequency distribution and percentage proportion. IBM SPSS version 22.0 was used for analysis.

Results and Observations

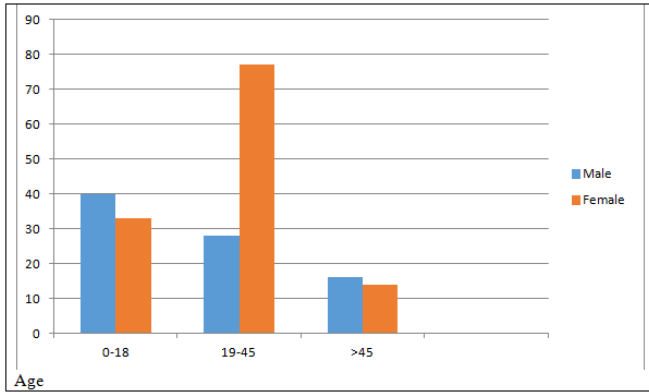
Table 1- Distribution of disease According to age

S.No.	Disease/Age	0-18	19-45	>45	Total Cases
1	Tuberculosis	18	67	9	94
2	Reactive lymphadenitis	24	58	18	100
3	Metastatic carcinoma	0	04	07	11
4	Lymphoma	01	00	02	03

As per table 1 the most common age group was found to be 19-45 years followed by 0-18 years. The most common disease was reactive lymphadenitis (48%) cases followed by tuberculosis in 46%. The criteria by which a diagnosis of reactive hyperplasia was established included high cell density, polymorphic patterns of cells and considerable number of tangible bodies macrophages. The aspirates from lymph nodes were diagnosed as tubercular lymphadenitis based on the presence of epithelioid cell granuloma and caseous necrosis with or without

langerhan’s giant cells in a milieu of parent lymphoid cells. Among these, 18 cases were Ziehl-Neelsen staining positive.

Figure 1- Distribution of cases According to Age and Sex



As per figure 1 females are more common in 19-45 years and therefore, they were the most affected by reactive LN and tuberculosis in the present study. The criteria by which a diagnosis of reactive hyperplasia was established included high cell density, polymorphic patterns of cells and considerable number of tingible body macrophages.

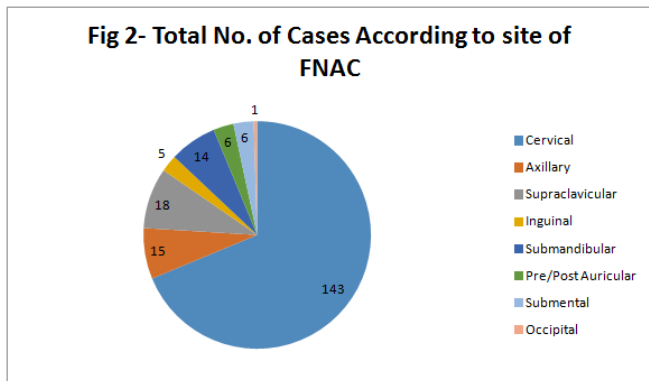


Figure 2- As per FNAC most common lymph node involved was cervical (72%) followed by supraclavicular (7%) and axillary. Inguinal are also common. So, it was concluded the most common site of lymphadenopathy was neck. Among the remaining cases, 18 were supraclavicular 14 were submandibular.

Table 2- Cytomorphological Feature of Tuberculosis

S.No.	Patterns	No of Cases - 94		AFB Positive (N-36)	% of AFB Positive
		Count	Percentage		
1	Epithelioid granuloma with necrosis	37	39.3%	15	40.5%
2	Epithelioid granuloma without necrosis	39	41.4%	4	10.2%
3	Necrosis without Epithelioid Granuloma	18	19.1%	17	94.4%

As per table 2 FNAC showed the cytomorphological feature of tuberculosis as seen epithelioid granuloma with necrosis for 39% of cases and without necrosis it is 41%. Only necrosis was seen in 19% but they have the highest number of AFB positive cases (94.4%).

Discussion

Fine needle aspiration cytology is a cost effective and at same time it is safer and suggests positive finding.⁴ No chance of scar in the operation for the patient. In the present study, female to male ratio was 1:0.9, with female preponderance, which was different with other studies.^{5,6} The lesions ascending in the lymph node can be found in patients ranging from early to advanced age. In our study the youngest patient was 19 years old and oldest was 75 years of age. These figures come in close comparison to other workers.² As regards the site of FNAC, cervical lymph node was the commonest site of involvement, as observed by other workers.^{1,3,5} Out of total 208 cases, 192 (93%) cases were benign and 16 (7%) cases were malignant lesions. These findings correlate well with the results reported by Sarda et al and Pamra SR et al.^{7,8} However, Steel et al reported 59% cases of malignant lesions and 34% cases of benign lesions.⁴ These changes in the results can be since western countries, where these studies were carried out show predominance of malignant conditions over benign conditions. In our study most of diseases are of reactive nature due to infections and of tubercular lesions, which are uncommon in western countries. This can be correlated with studies by other authors.^{9,10} In Our findings constituted

cytomorphological feature of tuberculosis showed 39% cases of Epithelioid granuloma with necrosis, which was also observed by Tilak et al.¹¹ Maximum number of correct diagnosis was obtained in metastatic nodes. Hajdu et al¹², in their study also noted that the common type of metastatic carcinoma to lymph node was squamous cell carcinoma.

Conclusion

FNAC of lymph nodes showed a useful tool in diagnosing both neoplastic and non-neoplastic lesions. It aids in planning surgery where definitive operative intervention can be performed.

Source of Funding- None

Conflict of Interest- None declared

References

1. Hirachand S, Lakhey M, Akhter J, Thapa B. Evaluation of fine needle aspiration cytology of lymph nodes in Kathmandu Medical College, Teaching hospital. *Kathmandu Univ Med J (KUMJ)*. 2009 Apr-Jun; 7 (26):139-42.
2. Wilkinson AR, Mahore SD, Maimoon SA. FNAC in the diagnosis of lymph node malignancies: A simple and sensitive tool. *Indian J Med Paediatr Oncol*. 2012 Jan; 33(1):21-4.
3. Sharma P, Rana S, Gill MK, Singh P, Satarkar RN, Kalhan et al. Spectrum of lymph node lesions on cytology in rural Haryana: a retrospective analysis. *Int J Res Med Sci*. 2015; 3(5): 1125-30.
4. Steel BL, Schwartz MR, Ibrahim R. Fine needle aspiration biopsy in diagnosis of lymphadenopathy in 1,103 patients. *Acta Cytologica*. 1995; 39: 76-81.
5. Ahmad SS, Akhtar S, Akhtar K, Naseem S, Mansoor T. Study of fine needle aspiration cytology in lymphadenopathy with special reference to Acid-fast staining in cases of tuberculosis. *JK Science*. 2005; 7: 1-4.
6. Saluja JG, Ajinyka MS. Comparative study of. Fine needle aspiration cytology, histopathology and bacteriology of enlarged lymph node. *Bombay hospital journal*. 2000; 42(2): 1-7.
7. Sarda AK, Bal S, Singh MK, Kapur MM. Fine needle aspiration cytology as a preliminary diagnostic procedure for asymptomatic cervical lymphadenopathy. *JAPI*. 1990; 38(3):203-5.
8. Pamra SR, Baily GVS, Gupta SP et al. Cervical lymphadenopathies. *Ind. J. Tub*. 1987: 96-100.
9. Patra AK, Nanda BK, Mahapatra BK, Panda AK. Diagnosis of lymphadenopathy by fine needle aspiration cytology. *Ind. J. Pathol. And Microbiol*. 1983; 26: 273-8.
10. Ansari SM, Zeenal AP, Tyagi SP. Tuberculous lymphadenopathy. *Indian Paediatr*. 1981; 18:293-6
11. Tilak V, Dhadel AV, Jain R. Fine needle aspiration cytology of head and neck masses. *Ind. J. Pathol. and Microbiol*. 2002;45(1):23-50.
12. Hajdu SI, Melamed MR. The diagnostic value of aspiration smears. *Am. J. Clin. Path*. 1973; 59:350-4.