



Idiopathic spontaneous pneumoperitoneum: a “not so rare” case report with diagnostic and treatment options

¹Allan L. Hilario, Department of Biochemistry and Molecular Biology, College of Medicine, University of the Philippines Manila, Manila, Philippines

²Donnatella V. Hilario, Surgical Service, San Diego de Alcala General Hospital, Gumaca, Quezon

Corresponding Author: Allan L. Hilario, Department of Biochemistry and Molecular Biology, College of Medicine, Manila 1000 Metro Manila, Philippines.

Citation this Article: Allan L. Hilario, Donnatella V. Hilario, “Idiopathic spontaneous pneumoperitoneum: a “not so rare” case report with diagnostic and treatment options”, IJMSIR- March - 2020, Vol – 5, Issue -2, P. No. 42 – 46.

Type of Publication: Case Report

Conflicts of Interest: Nil

Abstract

Idiopathic spontaneous pneumoperitoneum (ISP) is the presence of free air in the abdominal cavity without known surgical cause. This case has baffled the surgical community due to its challenging diagnosis and treatment. We reported a case of ISP and searched the literature to determine the rarity of this case. The patient was diagnosed with medical conditions and incidental finding of pneumoperitoneum was seen from the chest x-ray. However, patient was treated medically after a judicious surgical evaluation. Repeat chest x-ray showed resolution of pneumoperitoneum. This spared the patient from unnecessary surgery. The literature has already reported numerous case reports with similar outcomes and recommending a more conservative approach in diagnosis and treatment. ISP is no longer a rare disease.

Keywords: Spontaneous pneumoperitoneum, idiopathic, case report

Introduction

Since the report of idiopathic spontaneous pneumoperitoneum (ISP) by Guillemin in 1925, there are umpteen reports of ISP with different diagnostic,

therapeutic options, and various clinical outcomes in the literature claiming it to be rare. ISP is the presence of free air in the peritoneal cavity with apparently no identifiable cause or idiopathic in nature. Many surgeons consider this as a rare case of non-surgical pneumoperitoneum with various associated clinical conditions for its novelty, for its interesting educational value and contribution to the scientific knowledge about ISP [1].

What makes this benign and radiologic curiosity such an important clinical entity is its association with perforated or ruptured hollow viscus in the abdomen. Ninety percent of all pneumoperitoneum cases entail emergency laparotomy. Failure to perform appropriate surgery results in high mortality [2]. Although there are numerous reports of conservative management of ISP, many reported cases still undergo invasive and minimally invasive diagnostic procedures like diagnostic peritoneal lavage and abdominal laparoscopy to rule out perforated hollow viscus and air-producing peritonitis. Some underwent exploratory laparotomy with negative findings, making it more of a diagnostic tool and not a definitive surgical

management. The need to distinguish ISP from surgical pneumoperitoneum is very important due to the high mortality for neglected pneumoperitoneum secondary to surgical etiologies [3].

Although laparotomy is quite safe in this era of surgical practice, its conduct just to rule out any surgical causes of the pneumoperitoneum is unnecessary, unsafe, and costly. In this case report, we presented an adult patient with documented pneumoperitoneum and was treated conservatively due to medical pulmonary causes and no complication post-discharge.

Another objective in presenting the case was the realization that since the report of Guillemin and several decades later, the numerous reports of ISP with conservative management in both pediatric and adult patients provide significant understanding of this not so rare case entity anymore. It is now the right time towards the development of practice guideline for this condition.

Here, we searched PubMed and Embase using the mesh word “idiopathic spontaneous pneumoperitoneum”, excluding those that have surgical causes, to determine the number of reported cases of ISP, determine the diagnostic modality used to confirm the diagnosis, the treatment option done, the clinical outcomes and establish that this entity is not anymore rare, as many would perceive it to be. The case was presented to provide emphasis for our thesis. The SCARE statement: consensus-based surgical case report guidelines were followed [4].

Case Report

An elderly male consulted our hospital due to dyspnea and fever. Patient's condition started one week before admission with productive cough with on and off fever. Patient self-medicated with acetaminophen for one week, affording no relief. He was noted to be in mild

respiratory distress. Vital signs were: BR=120/80, CR=130, RR=32, and temperature=38°C. Intravenous fluids and oxygen inhalation at five Lpm via facemask were started. Pertinent physical examination showed labored breathing. Chest examination showed tachypnea with crackles and wheezes on both lung fields.

Patient was a smoker who stopped when diagnosed with chronic obstructive pulmonary disease (COPD) three years ago. Past medical history and review of the systems were unremarkable. He was admitted with an impression of pneumonia and chronic obstructive pulmonary disease in acute exacerbation. Routine laboratory examinations were done but the results were normal. He was started on cefuroxime 750 mg intravenously every eight hours, acetaminophen for fever, salbutamol/ipratropium

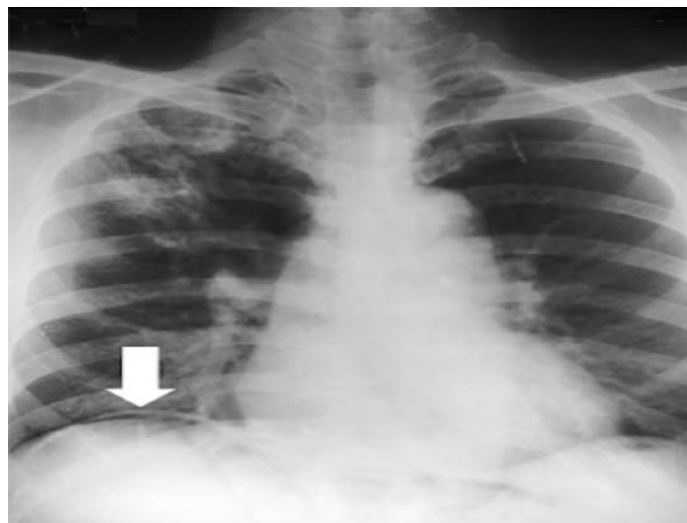


Figure 1: Chest radiograph with white block arrow pointing to the right hemidiaphragm and the radiolucent airstrip underneath the diaphragm.

nebulization every six hours and hydrocortisone 100 mg intravenously every six hours. Chest x-ray upright postero-anterior view was done and showed pneumonia with incidental finding of pneumoperitoneum as shown in Figures 1 and 2. Patient was referred to the surgical service. Patient's abdominal examination showed no

peritoneal signs and no generalized or localized tenderness. The case was diagnosed as ISP. Repeat abdominal examinations and strict observation were done. On the second hospital day, patient was afebrile, comfortable and no longer in respiratory distress. Repeat chest x-ray showed the same pneumonic lesion but absent

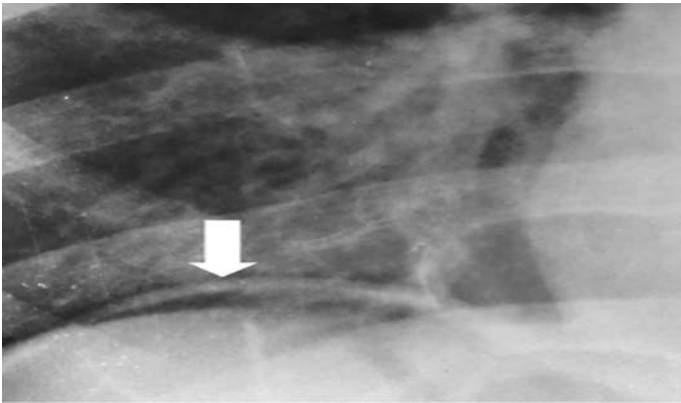


Figure 2: Enlarged part of the chest radiograph with white block arrow pointing to the pneumoperitoneum (Magnification 4X).

Pneumoperitoneum as shown in Figure 3. Discharged diagnoses were COPD in AE , pneumonia, and ISP. Abdominal CT scan was no longer requested. On follow- up thirty days after discharge, patient was essentially normal.

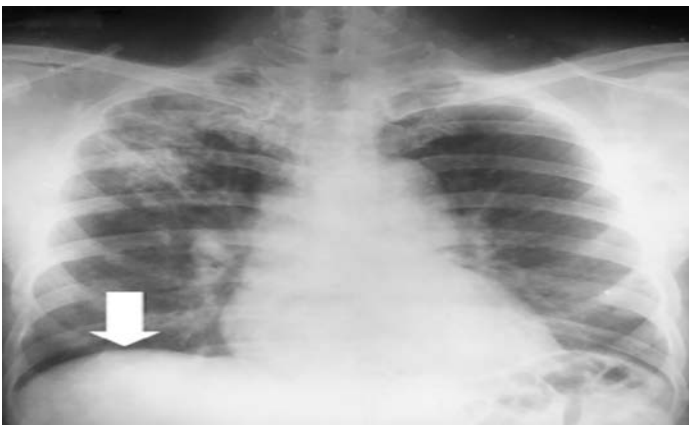

Figure 3: Chest radiograph taken after 24 hours showing resolution of pneumoperitoneum pointed by the white block arrow without the radiolucency under

the diaphragm. The characteristic right upper lobe lesion seen in Figure 1 can also be seen here.

Discussion

Since 1925 to present, there are 147 cases of ISP in both pediatric and adult patients using the search site PubMed and Embase. Some of these cases used diagnostic peritoneal lavage^[2] and abdominal laparoscopy [5] to rule out perforated abdominal hollow organs and the presence of air-producing bacterial peritonitis. Although these tests are minimally invasive, they pose significant risk and cost to patients with ISP who do not manifest any peritoneal signs of surgical abdomen.

In several case reports, exploratory laparotomy is performed to identify the cause of ISP. In most cases, the laparotomies show negative findings. These cases are diagnosed as ISP. In a case report by Hoover *et al*, SP without symptoms and signs of peritoneal irritation are treated with conservative management with no morbidity and mortality. These cases are monitored and followed up through the course of their hospitalization. Medical treatment is the only treatment modality used. An algorithm to safely manage patients with SP is reported in order to guide the clinicians in diagnosing and treating this condition. This algorithm can help clinicians to decide appropriately, decrease or totally avoid negative laparotomies and reduce healthcare cost [6].

Similarly, we advise surgical prudence in dealing with SP especially in a healthcare system sentient to the healthcare cost. These unnecessary procedures like diagnostic peritoneal lavage, abdominal laparoscopy, and abdominal laparotomy just to rule out the surgical cause of SP can be, at our present medical knowledge and evidence-based medical practice available, can be prevented and offer patients with ISP with a safer and

appropriate alternative in its diagnosis and treatment. Present medical knowledge generally points to treat conservatively. In the past few decades, this patient would have undergone exploratory laparotomy because of the surgical dictum, when free air is present in the abdominal cavity, air-filled organ is perforated and surgery is always indicated. This report and many others debunked this surgical principle. Pneumoperitoneum is not pathognomonic of perforated hollow viscus as many non-surgical causes can explain the presence of air in the peritoneum. These non-surgical causes include abdominal, intra-thoracic, gynecologic, barotrauma, thoracic barotrauma, and idiopathic. There are more interesting causes such as oral-vaginal insufflation, douching, and sports-related causes [7,8].

In this report, the possible non-surgical cause was probably due to Macklin effect, which is associated with bronchial asthma and chronic obstructive pulmonary disease in acute exacerbation that was present in our patient. Alveolar rupture is very prone in patients with emphysematous chronic obstructive pulmonary disease. This allows the air to escape and dissect along bronchoalveolar sheath. The free air causes pneumomediastinum. Free air may go to the different anatomical structures like the diaphragm and manifests as pneumoperitoneum [9].

Evidences available dictate that idiopathic ISP should be treated conservatively. Extensive reports on the non-surgical causes of ISP and management protocols like algorithms are well discussed and reported in the literature. This conservative approach includes judicious use of diagnostics procedures to ascertain non-surgical causes. Diagnostic peritoneal lavage, laparoscopy, exploratory laparotomy, and other imaging studies of the gastrointestinal tract are not

warranted unless clinical condition deteriorates. Repeat imaging studies like chest x-rays and CT-scan of the abdomen may be all that are needed.

Conclusion

Patients with idiopathic spontaneous pneumoperitoneum with no peritoneal signs, essentially normal in history and physical examination without generalized or localized abdominal tenderness should be treated conservatively. Such approach may avoid patients from unnecessary surgery and expensive healthcare cost. The number of reports of this clinical condition makes it no longer a rare case. The literature has enough evidence to provide evidence-based practice guidelines for this non-surgical condition.

Acknowledgment

The authors would like to acknowledge the approval and support of Dr. Dinna Blanca L. Valena of Calauag St. Peter General Hospital.

Patient Consent

The institutional ethics review committee of the hospital approved this case report. It was also registered with the Research Grants Administration Office of one of the author's academic institution. This study was also registered at <http://www.researchregistry.com> with a UIN of researchregistry3610. Informed consent was secured from the patient after informing him the use of his x-rays film in this case report and his clinical data from his medical chart, which does not contain his name or any identifying marks and kept on file. The consent and the case report were explained to the patient in his vernacular language. He was also allowed to read the copy of the case report.

References

1. A. Guillemin, "Roentgenoscopic diagnosis of gastrointestinal obstruction: spontaneous

- pneumoperitoneum.” Arch Franco-belges de chir. 1925; 68, pp. 684-702.
2. A. Karaman, S. Demirbilek, M. Akin, K. Gürünlüoğlu, C. Irşİ, “Does pneumoperitoneum always require laparotomy? Report of six cases and review of the literature.” *Pediatr Surg Int.* 2005; 21, pp. 819-24.
 3. R. A. Mularki, J. M. Sippel, M. L. Osborn., “Pneumoperitoneum: a review of non-surgical causes.” *Cri Care Med.* 2000; 28, pp. 38-44.
 4. R. A. Agha, A. J. Fowler, A. Saetta, I. Barai, S. Rajmihan, D. P. Orgill, for the SCARE Group. “The SCARE Statement: Consensus-based surgical case report guidelines.” *Int J Surg.* 2016; 34, pp. 180-6.
 5. M. Essarghani, M. Tarchouli, M. Elfahssi, A. Aitali, A. Bounamin. “A rare case of spontaneous massive pneumoperitoneum.” *Afr Pan Med J.* 2017; 26, p. 192.
 6. E. L. Hoover, G. D. Cole, L. S. Mitchell, C. Z. Adams Jr. “Avoiding laparotomy in non-surgical pneumoperitoneum.” *Am J Surg* 1992; 164, pp. 99-103.C. J. Kaufman, Rocky Mountain Research Lab., Boulder, CO, private communication, May 1995.
 7. F. Di Capua F. “Spontaneous pneumoperitoneum. Two case reports.” *Minerva Chir.* 1994; 49, pp. 719-21.
 8. W. R. Freitas Jr, C. A. Malheiros, P. Kassab, E. J. Ilias. “Idiopathic spontaneous pneumoperitoneum.” *Rev Assoc Med Bras.* 2011; 57, p. 614.
 9. Q. F. Masood, T. Khaleeq, Q. Khan, S. Abbasi, S. Arshad, F. Bano, D. Pervaiz. “A case of non-surgical pneumoperitoneum: gas under the diaphragm.” *J Ayub Med Coll Abbottabad.* 2009; 21, pp. 176-7.