



A Study on Radiological and Functional Assessment in Acute Diaphyseal Fractures of Radius and Ulna in Adults following plate Osteosynthesis

Dr.M.V.Sudhakar, Assistant Professor, Dept of Orthopaedics; Dr SM CSI Medical College, Karakonam, Kerala.

Corresponding Author: Dr.M.V.Sudhakar, Assistant Professor, Dept of Orthopaedics; Dr SM CSI Medical College, Karakonam, Kerala.

Citation this Article: Dr.M.V.Sudhakar, “A Study on Radiological and Functional Assessment in Acute Diaphyseal Fractures of Radius and Ulna in Adults following plate Osteosynthesis ”, IJMSIR- March - 2020, Vol – 5, Issue -2, P. No. 137 – 149.

Type of Publication: Original Research Article

Conflicts of Interest: Nil

Abstract

Aim: To study the radiological and functional outcome in acute diaphyseal fractures of radius and ulna following plate (3.5mm DCP SYSTEM) Osteosynthesis.

Materials and methods: This study was conducted between Jan 2001 and Dec. 2002, at Pushpagiri Institute of Medical Sciences & Research Centre, Thiruvalla, Kerala, India. There were 38 cases of acute diaphyseal fracture of radius and ulna in adults treated in this period., in which eight cases were open fractures. Among those 38 cases, 14 were treated with IM nailing or external fixator. One case was treated with IM nailing for ulna and plating for radius. The remaining 23 cases were treated with plate osteosynthesis. Two patients missed the follow up. This study consists of 21 cases (20 closed and one type 1 open) of acute diaphyseal fractures of the radius and ulna that were treated with plate osteosynthesis. In this study we have used AO 3.5mm DCP system and 3.5mm cortical screws (full threaded). Autogenous bone grafting was done4 whenever the comminution

was more than one third of the circumference of the cortex.

Results and Conclusion: Majority of the cases of adult acute diaphyseal fractures are due to road traffic accidents and are common in males. Internal fixation with 3.5mm dynamic compression plating provided satisfactory results in the treatment of diaphyseal fractures of ulna and radius. Early reduction and internal fixation with compression plates and screws provided satisfactory results. Time delay of three weeks did not alter the outcome in comparison with the original study operated within one week where the fixation was rigid.

Keywords: Fractures; Plates; Diaphysis; Fixation; Bone; Imaging.

Introduction

Civilization has its own drawback in this age increasing mechanization. The frequency of occurrence of fractures are enormously increasing day by day. Fractures of the forearm bones have become one of the most common injuries of day today life that are attended in the emergency services of the Orthopaedic department, owing to the factors of

increasing transport and industrialization. Although the literature is abundant on the management of forearm fractures, the success of treatment in severely displaced and complicated fractures remain highly unpredictable even in the hands of experienced surgeons. Even today there is no uniformity of opinion as to the best form of treatment to achieve an excellent functional result¹. Diaphyseal fractures of the radius and the ulna present specific problems not encountered in the treatment of fractures of the shaft of the long bones. In addition to the restoration of length²⁻⁴, apposition and normal axial alignment, correct rotational alignment must also be achieved if a good range of pronation and supination is to be restored⁵. Furthermore, there is a high incidence of malunion and nonunion because it is difficult to reduce and maintain the reduction of two mobile parallel bones⁶ in the presence of pronating and supinating muscles which exert angularity as well as the rotational forces. There are many reports on the results of displaced diaphyseal fractures of the forearm in adults⁸. Many methods have been employed including closed manipulation and immobilization in plaster cast and open reduction with or without internal fixation⁷⁻⁹. The special appliance used for internal fixation have included standard and special plates, Eggers slotted plate, the dynamic compression plate, primary only grafts and intramedullary fixation devices. In this study an attempt has been made to analyze the radiological and functional assessment in 21 patients with acute diaphyseal fractures of radius and ulna treated using 3.5mm dynamic compression plates.

Surgical Anatomy & Bio Mechanics

The radius is the lateral bone of the forearm. Its upper and lower ends are both expanded, but the lower end is much wider than the two. The shaft increases in breadth

rapidly towards the lower end and is convex to the lateral side and is concave forwards in its lower part. On transverse section it is triangular in outline but only one its borders, the interosseous border is sharp and easy to identify. The other two are anterior and posterior borders. The shaft has three surfaces- anterior, posterior and lateral. The roughened area at the middle of the lateral surface is situated at the region of maximum curvature and gives insertion to the pronator teres. The radius is the bone of multiple curves with rotator joint at either end¹¹. The medullary canal of the radius funnel shaped in its distal third, the stem of the funnel being the proximal two thirds of the radius. The canal in the middle third of the radius is curved in two planes simultaneously and is narrow. The ulna is the medial bone of the forearm and is parallel with the radius when the forearm is supine. The upper end is thick, strong and hooks like, the concavity of the hook being directed forwards. The lateral border of the shaft is a thin sharp crest. The bone diminishes in size its upper end to its lower end. The shaft is triangular on cross section in its upper three fourth, but is almost cylindrical in its lower fourth. The surfaces of the shaft are- anterior, posterior and medial¹². The borders- interosseous, posterior and anterior.

The articulation between the radius and ulna is in three parts, the proximal and the distal radioulnar joints and the shaft of the radius and the ulna are connected by the oblique cord and the interosseous membrane in the middle. The oblique cord is a small inconsistent flattened band or cord formed in the fascia overlying the deep head of the supinator and extending from the lateral side of the tuberosity of the ulna to the radius a little below the radial tuberosity. Its fibers run at right angles to those of the interosseous membrane¹³.

The interosseous membrane is broad and thin sheet. It almost completely bridges the separation between two bones from one radioulnar joint to the other. The fibers descend obliquely from distally on the ulna towards the radius proximally. Hence its long attachment throughout the length of the two bones resembles the hinge of a piano keyboard¹⁴. The transmission of forces from the hand to the radius thence to the ulna is throughout the diffused attachment of the interosseous membrane. If this force were transmitted over a less diffuse area considerable strain would center at one point of each of the bones and thus leads to much frequency of fractures of each. Also, this transmission of force is not a push, but a pull on the ulna from the radius due to the obliquity of the interosseous fibers. This pull tends to lessen the shock of the forces applied to the hand. Any encroachment on the interosseous membrane by ossification, malalignment or massive bone graft procedures produces restriction of motions of pronation or supination or both¹⁵⁻¹⁶.

Displaced diaphyseal fractures of the forearm bones are the most complex diaphyseal fractures of the body, from the standpoint of the restoration of normal function. One has to treat the diaphysis in relation to the other because of the arc of the radius, the relative length of one bone to the other and the interosseous hinge¹⁷. In treating diaphyseal fractures elsewhere in the body, alignment is the main factor and opposition can be off considerably, yet resultant function still can be normal. In treating diaphyseal fractures of the forearm alignment must be restored but also eventual opposition must be completely normal or some degree of limitation of pronation or supination will result. For obtaining an excellent result reduction of the displaced fractures of the diaphysis of the radius and ulna, must be anatomical. In the child anatomical restoration of

opposition is aided greatly by the organization which occurs during growth¹⁸⁻¹⁹. Once the bones break the direction and extent of displacement of the fractured fragments is dependent upon the level of fracture, muscle action and the direction of the breaking force. In the reduction and immobilization of these fractures, the origin, insertion and action of the forearm muscles must be considered. Knowledge of the deforming muscle forces are also important in emphasizing the utility of obtaining anatomical reposition of the fractured diaphysis by closed reduction.

The biceps brachii and supinator muscle are inserted into the proximal third of the radius; these muscles are the powerful supinators of the forearm. The pronator teres originating above the elbow medially inserts into the middle third of the radius. The pronator quadratus, located on the anterior aspect of the lower forearm inserts into the distal third of radius., immediately above the styloid process, the brachioradialis muscle assists in flexion and also the semi-pronator and semi-supinator of the forearm bringing it from the supine or prone position to neutral²⁰. The extensors of the wrist and digits have no deforming influence on the fracture fragments, but acts as a dynamic posterior splint when under tension as when the elbow is flexed. The extensors and abductors of the thumb act with brachioradialis muscle in the fracture of the distal third of the radius proximally. The powerful flexor muscles of the forearm tend to pull the distal fragments anteriorly and produce bowing of the radius and ulna during healing.

In fractures of the upper third of the forearm above the insertion of the pronator teres muscle the proximal fragment of the radius is supinated and flexed because of the unopposed action of the biceps brachii and supinator muscles and the distal fragment is pronated

by the action of the pronator teres and the pronator quadratus muscle. Therefore, to obtain alignment of the fracture the distal fragment must be supinated²¹. In Fracture middle third of the forearm below the insertion of the pronator teres the proximal fragment of the radius is held in neutral rotation as the action of the supinator muscle is counteracted by the pronator teres. The proximal fragment is drawn in to flexion by the action of the biceps muscle. The distal fragment is pronated and drawn outwards the ulna by the pronator quadratus muscle. To obtain anatomical reduction the distal fragment is brought in to neutral rotation midway between full supination and full pronation²².

In fractures of the lower third of the forearm, the distal fragment of the radius is pronated and drawn inward by the pronator quadratus muscle. The obliquity of the fracture line and pull of the muscles can cause overriding and shortening. Thus, in the lower third fractures, the forearm needs to be pronated, so that the proximal and distal fragments come in to alignment²³.

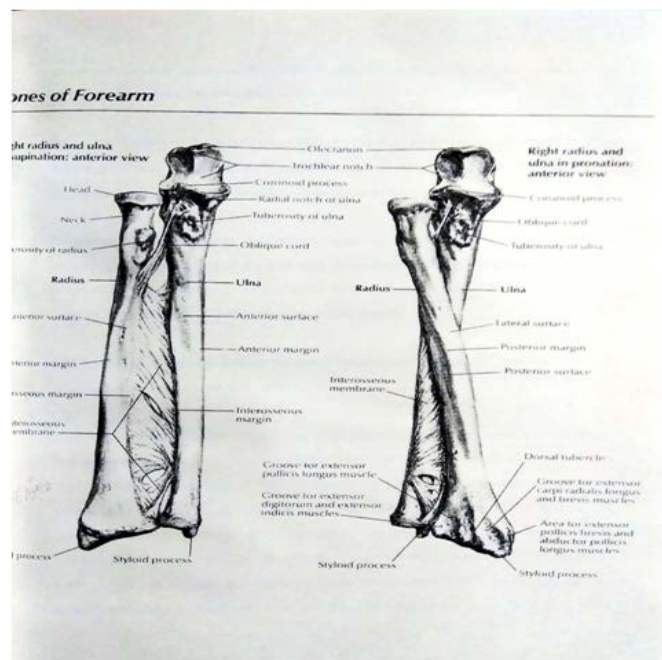


Figure 1

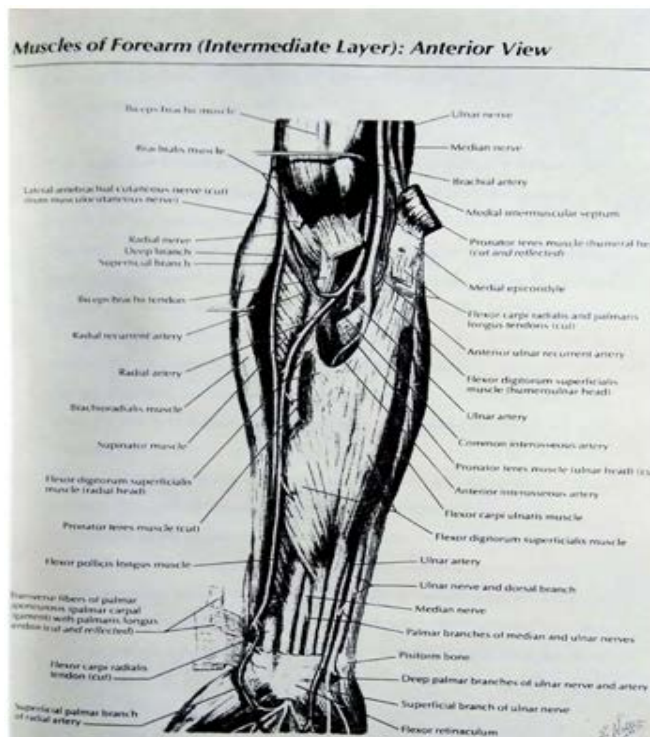


Figure 2

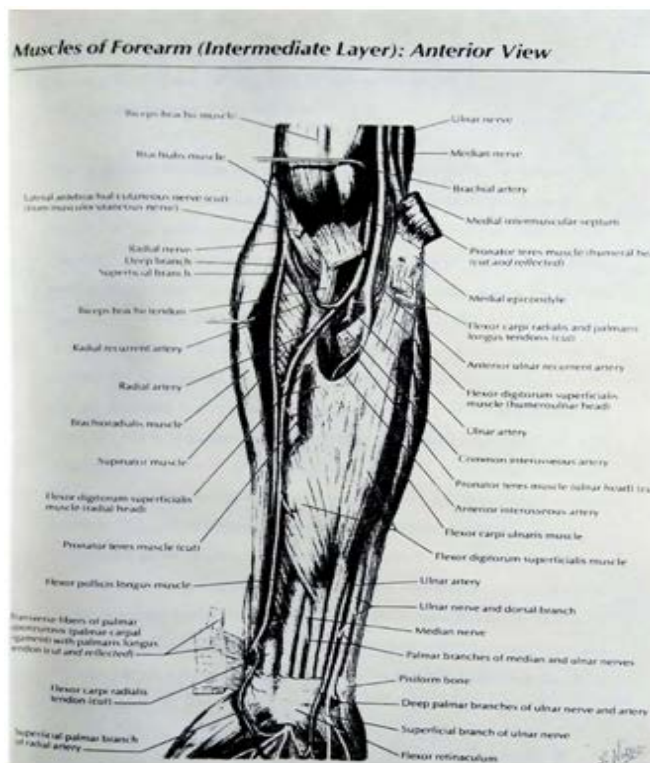


Figure 3

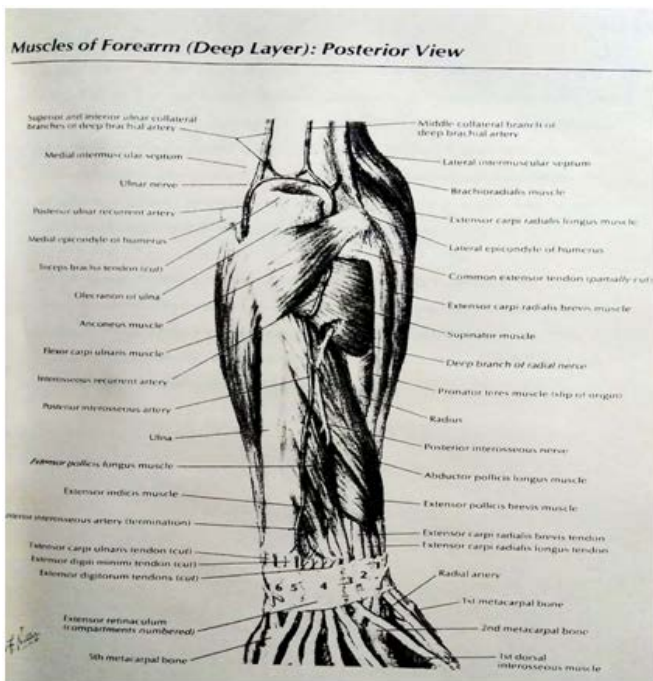


Figure 4

Classifications

AO Classification

The Diaphyseal Fractures of the Radius & Ulna are classified as follows

TYPE A	Simple fracture of radius and ulna
	Sub classified into
TYPE A1	Simple fracture of ulna
TYPE A2	Simple fracture of radius
TYPE A3	Simple fracture of radius and ulna
TYPE B	Wedge fracture of radius and ulna
	Sub classified in to
TYPE B1	Wedge fracture of ulna
TYPE B2	Wedge fracture of radius

TYPE B3 Wedge fracture of radius and ulna

TYPE C Complex fracture of radius and ulna

The AO classification of forearm fractures are based on the fracture patterns designed as simple , Wedge and complex (Type A,B, and C respectively). Sub classification of isolated ulna, isolated radius and one or both bone fractures are subclassified in to 1,2, and 3 respectively.

Sub classified in to

TYPE C1: Complex fracture of ulna and simple fracture of radius

TYPE C2: Complex fracture of radius and simple fracture of ulna

TYPE C3: Complex fracture of ulna and radius

Orthopaedic Trauma Association (OTA) System

Type1	Transverse fracture
Type 2	Oblique
Fracture(>30%)	
Type 3	Spiral fracture
Type 4	Spiral or Oblique fracture with butterfly Fragment
Type 4 a	Spiral or Oblique fracture with butterfly(<50%)
Type4b	Spiral or Oblique fracture with butterfly(>50%)
Type 5	Comminuted fracture
Type 5a	Comminuted fracture(<50%)
Type 5b	Comminuted fracture(>50%)
Type 6	Segmental fracture
Type 7	Bone loss
Type 7a	Bone loss(<50%)

Type 7 b

Bone loss(>50%)

The OTA classification of forearm fracture reflects the complexity of the fracture pattern and ranges from a simple transverse injury (Type1) through to injuries with segmental bone loss (type 7) . The comminuted fractures are sub classified in to A or B depending on circumferential bony involvement (less or greater than 50 percent) on the extent of multifragmentation.

According To the Level Of Fracture

Its classified in to Upper third Middle third Lower third

Materials And Methods

After learning the advantages of plate osteosynthesis in acute diaphyseal fractures of both bones of forearm , this study was undertaken to study the radiological and functional outcome following plate osteosynthesis.

Materials

This study was conducted between Jan 2001 and Dec. 2002, at Pushpagiri Institute of Medical Sciences & Research Centre, Thiruvalla, Kerala, India. There were 38 cases of acute diaphyseal fracture of radius and ulna in adults treated in this period., in which eight cases were open fractures. Among those 38 cases, 14 were treated with IM nailing or external fixator. One case was treated with IM nailing for ulna and plating for radius. The remaining 23 cases were treated with plate osteosynthesis. Two patients missed the follow up. This study consists of 21 cases (20 closed and one type 1 open) of acute diaphyseal fractures of the radius and ulna that were treated with plate osteosynthesis. In this study we have used AO 3.5mm DCP system and 3.5mm cortical screws (full threaded). Autogenous bone grafting was done4 whenever the comminution was more than one third of the circumference of the cortex.

Pre Operative Assessment

Patient Profile

There were 12 male cases and 9 female cases. Among 21 cases 11 cases had fracture of right forearm and 10 patients their left forearm. One patient had fracture at the proximal end of the plate following union of the previous fracture. This study had 21 cases. Most of them were of 30-39 age groups.

Age group	No of patients
20-29	5
30-39	8
40-49	2
50-59	3
>60	3

Investigations

Ematology: Blood routine, CT<BT< grouping and Rh-typing, Urea and creatinine

Radiogram: Routine antero-posterior and lateral views of injured Forearm including elbow and wrist.

Mechanism of Injury

Classified basing on degree of violence as

- 1.Low velocity injury
- 2.High velocity injury

Classification

All the patients are classified into two types.

1. An orbital classification of
 - Simple (transverse/ oblique/ spiral)
 - Comminuted
 - Segmental

We had 8 simple and 13 comminuted fractures and no segmental fracture in our study.

2. Using AO classification

Type A3	(Simple)
Type B3	(Wedge)
Type C1/C2/C3	(complex)

We had 8 simple , 12 Wedge types and 1 complex fracture in our study.

Type of Fracture

In our study we had 20 closed fractures and one type 1 open(Gustilo's) fracture.

Associated Injuries

Head injury	2
Spine injury	1
Fracture pelvis	1
Fracture femur and tibia	2
Fracture femur	3
Fracture tibia	3
Fractures scapula and ribs	1
Blunt injury abdomen	1
Dislocation of ipsilateral	
Radial head	1

Isolated cases of fracture of both bones of forearm

Treatment Protocol Immediate Closed Fracture

These fractures were initially treated with temporary stabilization using above elbow posterior plaster slab.

Open Fracture

These fractures were initially treated with primary wound debridement. Closed reduction and immobilization in a posterior plaster slab under antibiotic cover . Later-on patients were on regular wound dressing till the wound healed

Definitive Treatment Surgical Technique

All patients were treated within three weeks of the injury. The radius and ulna were approached through separate incisions.

ULNA

The ulna was exposed by an incision along subcutaneous border posteriorly.

Radius

The proximal one third of the radius was exposed by Thompson approach. Distal one third and middle one

third of the radius was exposed by Henr's approach. Only that surface of the bone on which plate is to be placed was exposed by subperiosteal dissection. The fracture site interdigitations were cleaned of fracture hematoma and soft tissue. The fracture is then reduced to plate bone combination. This technique necessitates less soft tissue dissection and makes it relatively simple to handle intercalary comminuted bone fragments as well. Six separate cortices of solid screw fixation were attempted through a plate wherever indicated. Bone grafting was done where there was comminution involving more one third of the circumference of cortex.

First generation cephalosporins (cefazolin0 or second generation (cefuroxime) was used for antibiotic prophylaxis. A 3.0mm dynamic compression plate system was used for fixation in all 21 cases. In one patient who had sustained a fresh fracture at the proximal end of the plate of an old united fracture., the previous plates were removed and a new DCP was used for fixation. For one patient who had ipsilateral radial head dislocation, dislocation reduced initially under image intensifier and the fracture was stabilized with 3.5mm DCP system.

Hemostasis achieved after releasing the tourniquet and the wound was closed following betadine-saline irrigation of the surgical site. Vicryl 2.0 and Nylon 3.0 were used for closure of the subcutaneous and skin respectively. Suction drains were used in all cases.

Post operative care

Sterile dressing was given at the surgical site. Forearm was placed in a bulky soft cotton roll and above elbow posterior plaster slab was applied. Drains were removed after 48 hours. Sutures were removed on the 10th/14th postoperative day. Later on a above elbow posterior plaster slab was given and patient was

discharged (except polytrauma cases) . Check X-rays were done on the first post operative day in most of the cases. Active finger , shoulder movements and isometric exercises were taught and encouraged.

Follow UP

All the patients were reviewed at six weeks interval (ie. 6th week, 12-14 weeks, 18-20 week,24-26 week and after 26 weeks) until the union is achieved, except two patients who had achieved union by 10th week. In each visit patients were subjected to clinical and radiological assessment of union.

Functional assessment was done by examining the degree of pronation and supination at the time of union. In each visit patients were assessed for surgical site infection.

Surgical Site Infection

Surgical site infection was diagnosed by clinical features like persistent fever, pain or discharge from the surgical site. It is classified as superficial infection if it hasn't crossed the deep fascia and deep infection if it has crossed the deep fascia and or involving the fracture per se and implant. We had no incidence of deep infection but we had one case of superficial infection which had healed with sterile dressing.

Assessment Of Union

Determination of union/ delayed union union/ non union was assessed by using the **criteria of Anderson et al (1975)**.

Extension of trabeculae across the fracture.

Obliteration of the fracture line.

Bridging callus

Union : The fracture that healed by six months.

Delayed Union : The fracture that healed after six months without additional operative procedure.

Non Union: The fracture that failed to unite even after six months or that needed an additional operative procedure.

Functional Assessment

Using the **criteria of Anderson et al 1975**, The result were graded as follows;

1. Good : Union of fracture with loss of pronation and supination of <25%

2. Fair : Union of fracture with loss of pronation and supination of <50%

3. Poor : Union of fracture with loss of pronation and supination of >50%

Complications: Surgical site infection either superficial or deep Compartment syndrome and Volkman's ischemic contracture Stiffness of forearm or fingers

Delayed union

Non union

Infective

Non infective

Statistical Methods Adopted

Statistical methods adopted in this study are

Frequency distribution tables.

Pie charts

Simple Bar Charts

Limitations And Ethical Issues

The patient information was gathered from the outpatient and inpatient records documented in each visit.

Analysis & Observations: Any study where clinical assessment is the parameter ,the judgement is subject to variation. The following epidemiological observations were studied in addition to radiological and functional assessment.

The results were discussed under

A Epidemiological results

B Radiological results

C functional results

Epidemiological Results

1. Male/ Female Ratio (Sex Incidence)

There were 12 male (57%) and 9 female (43%) patients. The male, female ratio was 1:3:1

2. Age Incidence (Distribution)

There were 5 patients between 20-29 years, 8 patients between 30-39 years, 2 patients between 40-49 years, 3 patients between 50-59 and 3 patients were aged 60 years and above.

Maximum numbers of patients were young adults in the age group of 20-29 years (13 Patients 62%)

3. Laterality: Affection of either right-11 cases (52%) or left -10 cases (48%) showed that both sides were almost equally involved.

Mechanism Of Injury: Most of the cases were due to road traffic accidents. Cases injured in road traffic accidents were 12 (57%) and due to fall were 9 (43%). Most of the patients who have sustained a road traffic accidents were males.

Fracture Classification

AO classification was used

Type of fracture	Number of patients
Type A3	08 (38%)
Type B3	12
(57%)	
Type C1	01
(05%)	

Type of Fracture (Open/ Closed)

In our study we had 20 closed cases and one Type 1 (Anderson and Gustilo) open fracture

Associated Injuries: Among The 21 Cases Studied , There Were 15 Cases Of Isolated Fracture Both Bones Forearm . In The Remaining Cases,

2 Patient Had Head Injury

1 Patient Had Pelvic Injury

3 Patient Had Fracture Femur

3 Patient Had Fracture Tibia

2 Patients Had Fracture Femur And Tibia

1 Patient Had Ipsilateral Radial Head Dislocation

1 Patient Had Fracture Scapula And Ribs

1 Patient Had Blunt Injury Abdomen.

Radiological Assessment

For All The Cases Sufficient Follow Up Data Was Available To Evaluate The Union. Union Was Assessed Using The Criteria Of Anderson Et Al (1975)

1. Extension Of Trabeculae Across The Fracture.

2. Obliteration Of The Fracture Line.

3. Bridging Callus

➤ Union Occurred In 95.2% (20 Cases) Of The Patients

➤ No Delayed Union In Our Study

➤ One Case Went For Non-Union Of Ulna With Implant Failure (Loosened Plate) 4.8%.

➤ The Average Time For Union Was 14.6 Weeks In Our Study.

➤ Minimum Period Of Union Was 10 Weeks In Two Of Our Patients.

➤ Maximum Period Of Union Was 24 Weeks In One Our Patient.

Functional Assessment

At The Follow Up Functional Results Were Available For All The Patients.

A Anderson Et Al (1975) Criteria Was Used For Analysis Of The Results.

Good : In 18 Patients (85.7%)

Fair : In 2 Patient (9.5%)

POOR : In 1 Patient (4.8%)

Complications: One patient had superficial surgical site infection and hypertrophic scar. Other 20 cases did not have any infection.

Discussion

Diaphyseal fractures involving both bones of the forearm are one of the most common injuries in trauma care service. They occur as part of polyskeletal trauma or as isolated injuries.

Clinical and radiological assessment was carried out in 21 patients with diaphyseal fractures of both bones of forearm treated by open reduction and plate osteosynthesis and this has been compared with the historical control study.

The difference in the rate of union was compared with that of Anderson et al series (1975) and chapman et al (1989) series. The average union time for both bones forearm fracture in our study was 14.6 weeks, when compared with 12 weeks of Anderson et al series and 14 weeks in Chapman et al series. In our study the range was from 10 weeks to 24 weeks, in Anderson et al series it was 8 to 24 weeks and Chapman et al series it was from 10 to 24 weeks.

Rate of union was 95.2% in our study; it was 97% in Anderson et al series and 94% in Chapman et al series. There was no delayed union in our study as compared to 1.5% in Anderson et al series and 4% in Chapman et al series. The rate of union was 4.8% in our study compared to 1.5% in Anderson et al series and 2% in Chapman series.

In our study we did not have any case of delayed union. One case went for nonunion, because patient compliance was poor. Premature use of the limb against Medical advice and irregular follow up resulted in implant failure (loosening of the ulnar plate) with nonunion of ulna and delayed union of radius.

She had denied further additional procedure in our center. She had taken the radiographs along with her so they were not available for documentation in the study. So the patient medical records were made use for collecting clinical and radiological data.

Table 1: showing radiological outcome of our study

	Anderson et al series	Chapman et al series	Our study
Average time taken for union (weeks)	12	14	14.6
Union (%)	97%	94%	95.2%
Delayed union (%)	1.5%	4%	0%
Non union (%)	1.5%	2%	4.8%

In our study we have treated 15 cases within the first week, 4 cases in the second week and 2 cases in the third week following injury.

Though the surgery was delayed for three weeks in two cases, one who had bronchial asthma and the other had failed closed reduction done elsewhere, the latter case had achieved union within 10 weeks. Primary bone grafting was done in this case.

This is compared with the chapman et al series where there was no change in the time taken for union due to delay in fixation more than a week.

Among the 21 patients studied 7 patients underwent primary bone grafting. All had union within 14 weeks.

The rate of functional outcome in our study was compared to that Anderson et al and Chapman et al series. **In our study 85.7% had good functional outcome** when compared to the 91% in Anderson et al series and 92% in Chapman series.

Fair functional outcome was 9.5% in our study, 7% in Anderson et al and 5% in Chapman et al series. The case was found to be the use of long screws for fixation of the plate in one patient and in the other case it was due to ipsilateral radial head dislocation.

The outcome of poor result in our study was 4.8% and it was 2% in Anderson et al and 3% in Chapman series.

Table 2: showing functional outcome of our study

Functional outcome	Anderson et al series	Chapman et al series	Our study
GOOD	91%	92%	85.7%
FAIR	7%	5%	9.5%
POOR	2%	3%	4.8%

The philosophy of surgical treatment and post-operative care adopted in our study was primary bone grafting if the comminution is involving more than one third of the circumference. We routinely gave posterior plaster slab for a total period of 4-6 weeks for healing of interosseous membrane.

The rate of infection in our study was 4.8%. This was higher than that of Anderson et al (2.9%) and Chapman et al series (2.3%). The infection was superficial involving the skin only. Infection was diagnosed based on local signs and culture report. However, the culture report was negative in our study.

Infection was controlled by oral antibiotics and sterile local dressings. Patient did not require any surgical debridement in our study for control of infection.

Table 3: showing complications of our study

Complication	Anderson et al	Chapman et al	Our study
Infection (%)	2.9	2.3	4.8
Non union (%)	1.5%	2%	4.8%

We had one case with fracture at the proximal end of the implant following the union of fracture at the end of 16 weeks following a fall.

The 3.5mm dynamic compression plate with 3.5mm cortical screws used for fracture of radius and ulna. These implants were selected following the observation of Anderson et al who reported refracture after removal of 4.5mm compression plate, but not after removing 3.5mm compression plate and concluded that 4.5mm compression plate is too large for most of the fractures of radius and ulna and recommended 3.5mm compression plate for fracture of radius and ulna.

In our study we had the opportunity to remove implants in three cases after 20 months of surgery with radiological and clinical union which did not cause any refracture. The potential advantage of immediate internal fixation with plates and screws include restoration of stability, normal anatomical alignment, earlier initiation of range of motion exercises and good functional results.

Summary & Conclusion

1. Majority of the cases of adult acute diaphyseal fractures are due to road traffic accidents and are common in males.
2. Internal fixation with 3.5mm dynamic compression plating provided satisfactory results in the treatment of diaphyseal fractures of ulna and radius.
3. Early reduction and internal fixation with compression plates and screws provided satisfactory results.
4. Time delay of three weeks did not alter the outcome in comparison with the original study operated within one week where the fixation was rigid.

5. When fixation was adequate and anatomical alignment is good bone grafting as an additional procedure is not indicated in fresh fractures.
6. Primary bone grafting in case of comminution involving more than one third of the circumference resulted in union within 14 weeks.
7. Associated injuries like superior and or inferior radio-ulnar joint disruptions may adversely affect the functional outcome.(We had one case with ipsilateral radial head dislocation, who had FAIR functional outcome).
8. Undependable persons may require post operatively external splintage and thorough education.
9. All the patients should be advised and warned about untoward consequences like delayed union, non-union, implant failure due to premature activity and refracture following implant removal

References

1. NDERSON LD:SISK.T.D., TOOMS.R.E. Compression plate fixation in acute diaphyseal fracture of radius and ulna JBJS-57a-287297- 1975
2. BAGBY G.W & JANES J.M The effect of compression plate on the rate of healing using a special plate JBJS-9A-761-771-1958
3. BURWELL H.N; treatment of forearm fractures in adult with particular reference to plate Fixation JBJS 468: 404, 1964
4. CAMPBELL W. C & BOYD HB; Fixation of onlay bone grafts by means of vitalium screws in the treatment of non-united fracture American journal of surgery 51-748-756- 1941
5. CHAPMAN M.W.GORDEN J.E, ZISSIMOS A.G; Compression plate fixation of the fractures of the diaphysis of the radius and ulna JBJS; 71A; 159; 1989
6. DODGE H.S.AND CODY G.W; Treatment of fracture of the radius and ulna with compression plate – JBJS- 59A-1167-1176-7972
7. EGGERS G.W.N, SHINDLER T.O., POMERAT C.M; The influence of contact – compression factors on osteogenesis in surgical fractures JBJS Am 1949,31:693
8. EGGERS ET AL; Internal contact splint- JBJS- 30A -40-52-1942
9. HADDEN W.A., RESCHAUER.R, SEGGLI.W. Results of AO plate fixation of forearm shaft fractures in adult; 1982; 15:44
10. HESTEL .R, LAMBERT. S., BALLNER.F.T. ET AL Plate osteosynthesis of diaphyseal fractures of radius and ulna 1996;8:545
11. HICKS J.H; Fractures of forearm treated by rigid fixation JBJS 1961; 43:680
12. HIDAKA AND GUSBIO R.B; Refracture of bones of the forearm after plate removal JBJS- 66A- 1241-1248- 1983
13. HOPPENFIELD; Surgical approaches, second edition 118-146
14. GRACE T.G. Forearm fractures – treatment by rigid fixation with early motion JBJS 62 A; 433, 1980
15. JIMKENS W.J,LOCKHART L.D.& EGGERS G.W.N; Fractures of the forearm in adults South Medical journal 53-669-679-1960
16. KNIGHT R.A. PURVIS G.D; Fracture of the both bones in adult JBJS Am 1949; 31; 775
17. LAST R.J.Anatomy; Second Edition
18. MIDGLEY R.D; Volkmann ischemic contracture of the forearm Ortho. Clin. NA 1973; 4:983
19. MIHAD , COONEY W.P, FALER R.S, LEWALTER D.G; Long term follow up of

forearm bone diaphyseal plating Clin. Orthro 1944;
299:256

20. MULLERM.E.ALLGOWER M. AND WILLENGGER; Technique of internal fixation of fractures second edition Springer and Veiaq 1965
21. NAIMAN P.T , SCHEIN A.J AND SIFFERT R.S; Use of ASIF compression plates in selected shaft fractures of upper extremity Clinic. Orthro. 71-208-216-1970
22. NETTAR F; 2ND Edition; Orthopedic atlas; ISSN=2376-1245-21687; pages (31-54)
23. ROSACKER J.A & KOPTA J.A; Both bones fracture of the forearm , A review of surgical variable associated with union . Clinic Orthro- 80-1353-1356; 1981.