

Umbilical Pilonidal Sinus: A Rare Case Report

¹Dr. Sheela K.M, Associate Professor (Non-cadre), Govt. Medical College, Thiruvananthapuram

²Dr. Sithara Sathar, Junieur Resident, Govt. Medical College, Thiruvananthapuram

Corresponding Author: Dr. Sheela K.M, Associate Professor (Non-cadre), Govt. Medical College, Thiruvananthapuram

Citation this Article: Dr. Sheela K.M, Dr. Sithara Sathar, “Umbilical Pilonidal Sinus: A Rare Case Report”, IJMSIR- December - 2020, Vol – 5, Issue - 6, P. No. 16 – 18.

Type of Publication: Case Report

Conflicts of Interest: Nil

Abstract

Umbilical pilonidal sinus is a rare condition that comes under diseases of the umbilical region. These are usually seen in young adolescent males who usually have hairy abdomen or a deep naval or both. The most common presentation is umbilical pain followed by discharge. Careful inspection and presence of deep seated hair in sinus cavity can lead to a clinical diagnosis. Confirmation can be done by microscopy by the keratinized stratified squamous epithelial lining of sinus tract and the presence of hair follicles or broken hair shaft in the cavity with accompanying inflammation. In this paper we are presenting one such case of an umbilical pilonidal sinus.

Keywords: Umbilical Pilonidal Sinus, Histopathology.

Introduction

Pilonidal sinus is a chronic granulomatous inflammatory disease with tissue reaction to fragments of broken hair shaft which may enter into the dermis through dilated hair follicle. It was first described by Herbert Mayo in 1833 in the region of sacrococcyx ^[1]. Pilonidal sinus at the site of umbilicus was first described in the year 1956^[1]. It is a rare site and accounts for 0.6% of all pilonidal disease. Until now

only around hundred cases of umbilical pilonidal sinus has been mentioned in literature of medicine.^[2]

Case report

A 19 year old male presented with complaints of recurrent discharge from umbilicus for the past 7 to 8 months. Initial symptom was umbilical pain followed by umbilical discharge. The discharge was usually serous and occasionally mixed with pus. There was no history of any trauma to the umbilical region. There was no similar history in the past. There is presence of plenty of abdominal hair around the umbilicus and history of poor personal hygiene.

Clinically a diagnosis of umbilical pilonidal sinus was made and MRI was taken which was reported as suggestive of umbilical pilonidal sinus or omphalitis. Patient was started on antibiotics and anti-inflammatory drugs. The patient underwent umbilectomy procedure.

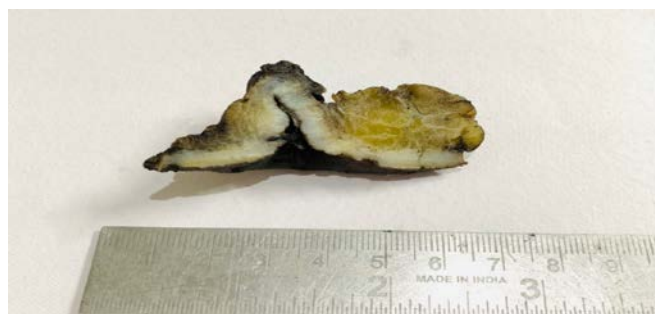

Figure 1: Umbilectomy specimen showing a sinus tract of length 1.5cm

On close inspection hair fragments could be seen along the sinus cavity. Surrounding tissue appears unremarkable.

He was then discharged with advice of maintaining local hygiene, advised to wear loose airy clothing and do regular depilation of hair in the affected area.

Microscopy of the lesion showed a sinus tract lined by keratinized stratified squamous epithelium. Also noted many broken hair shafts and hair follicles in the cavity. Few scattered inflammatory cells were seen in the surrounding tissue.

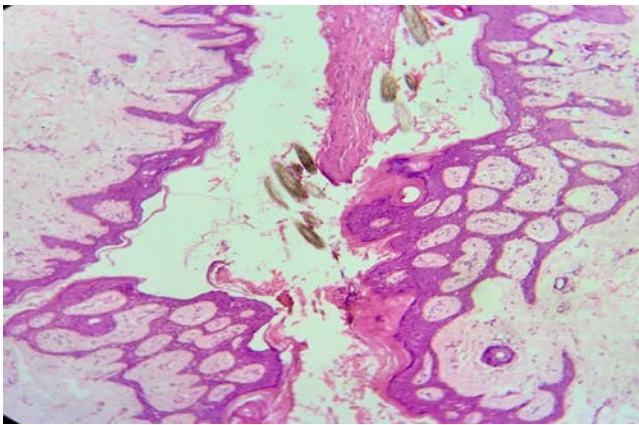


Figure 2: The sinus tract is lined by keratinized stratified squamous epithelium. Sinus cavity shows numerous hair follicles and broken hair shafts.

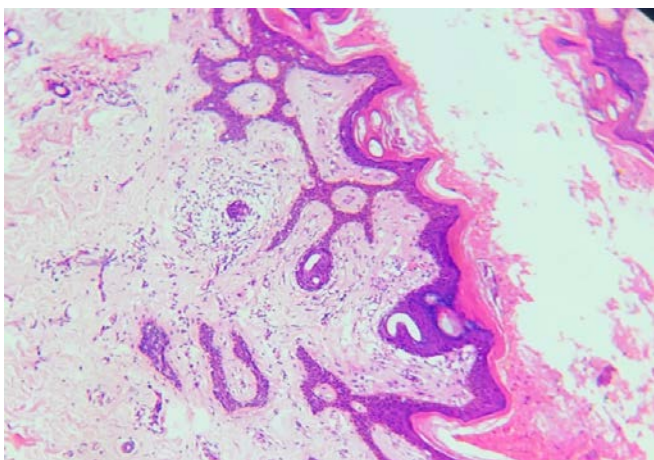


Figure 3: Surrounding tissue shows scattered inflammatory cell infiltrates composed of lymphocytes, plasma cells and histiocytes. Inflammatory component

was relatively reduced in our case as the patient was already started on antibiotics and anti inflammatory drugs.

Discussion

Umbilical pilonidal sinus is a rare entity whose aetiopathogenesis is not clear. Originally it was considered to be congenital. Later it was proved to have an acquired nature^[2]. Broken hair shafts may enter the subcutis through stretched hair follicle. This elicits a foreign body reaction by the host tissue. This may lead to a sinus tract being formed which is lined by granulation tissue^[3]. If this tract is infected, patient may present as abscess formation at the site.

Various studies have been done to find out the contributory factors leading to formation of an umbilical pilonidal sinus. Some of them are adolescent boys, obesity, use of tight clothing, presence of abundant body hair, naval which is deep and hairy and improper personal hygiene^[4].

Umbilical pilonidal sinus is usually a clinical diagnosis. Additional investigations are not usually required. The presence of deep seated hair in the cavity is clearly suggestive of the disease. Most common presenting symptom is umbilical pain, followed by bloody discharge^[5]. If there is secondary infection, the discharge may be purulent.

In case the clinician is suspecting other differentials, they may ask for an MRI to be done for confirmation. Other differential diagnosis can include umbilical hernia, epidermoid cyst, endometriosis (if female), pyogenic granuloma, metastatic tumors, and urachus^[3]. Microscopy of umbilical pilonidal sinus will show a sinus tract lined by keratinized stratified squamous epithelium. Cavity can show hair follicles and broken hair shaft. Usually dense inflammatory cell infiltration can be seen composed of lymphocytes, plasma cells

and histiocytes. Few polymorphs may be seen. Numerous foreign body giant cells may also be seen around the hair shafts^[6].

As this is a rare entity, there are no definite guidelines of treatment. Conservative management is considered first in more than half of the cases⁽⁵⁾. Asymptomatic patients are advised to practice good personal hygiene. The surgeon may proceed with hair removal from sinus tract and patient may be sent home with advices regarding avoidance of tight clothing and to regularly depilate hair in the affected area. If extraction of hair is not complete, then conservative management may fail⁽¹⁾.

In repeated failure of conservative management, umbilectomy or complete excision of sinus can be done, and if required it can be followed by reconstructive procedure^[5].

References

1. Al-Kadi AS. Umbilical Pilonidal Sinus. *International Journal of Health Sciences*. 2014;8(3):308–10.
2. Meher S, Mishra TS, Sasmal PK, Sharma R, Rout B. Umbilical Pilonidal Sinus: A Report of Two Cases and Recent Update of Literature. *Journal of Clinical and Diagnostic Research : JCDR*. 2016 Sep;10(9):PD20-PD22. DOI: 10.7860/jcdr/2016/20251.8569.
3. McClenathan JH. Umbilical pilonidal sinus. *Canadian Journal of Surgery*. 2000 Jun;43(3):225
4. Eryilmaz, R., Sahin, M., Okan, I., Alimoglu, O. and Somay, A., 2005. Umbilical pilonidal sinus disease: predisposing factors and treatment. *World journal of surgery*, 29(9), pp.1158-1160.
5. Salih AM, Kakamad FH, Essa RA, Mohammed SH, Salih RQ, Othman S, Hammood ZD, Saeed YA. Pilonidal sinus of the umbilicus: Presentation and management. *Edorium J Gastrointest Surg* 2017;4:1– 4.
6. Ndenaa, K. and Pollard, M.L. (1995), *Histology of chronic pilonidal sinus*. *APMIS*, 103: 267-272