

## **Anaesthetic Management in Laparoscopic Bilateral Adrenalectomy**

<sup>1</sup>Dr Pranami Nautamkumar K, <sup>2</sup>Dr Hima Patel, <sup>3</sup>Dr Sachina Gamit, <sup>4</sup>Dr Vashisth Vaidya, <sup>5</sup>Dr Viral Trivedi, <sup>6</sup>Dr Beena Parikh

**Corresponding Author:** Dr Pranami Nautamkumar K

**Citation this Article:** Dr Pranami Nautamkumar K, Dr Hima Patel, Dr Sachina Gamit, Dr Vashisth Vaidya, Dr Viral Trivedi, Dr Beena Parikh, “Anaesthetic Management in Laparoscopic Bilateral Adrenalectomy”, IJMSIR- December - 2020, Vol – 5, Issue - 6, P. No. 43 – 46.

**Type of Publication:** Case Report

**Conflicts of Interest:** Nil

### **Introduction**

Pheochromocytoma is rare neuroendocrine tumour of medulla of adrenal glands. Originates from chromaffin cells along the paravertebral sympathetic chain extending from pelvis to base of skull. Secretes excessive amount of adrenaline, noradrenaline & dopamine > 95 % Abdominal > 90 % Adrenal medulla > 80% Occur unilateral. Bilateral adrenal pheochromocytoma is uncommon & complex procedure. Occurrence is 2-8 cases in a million. Secondary cause of hypertension in 0.1% patients. Age 20-50 years. If it diagnosed during induction of anaesthesia → hypertensive crisis → mortality close to 80%.

### **Case Report**

Here our case of 26 Year old male Patient with past H/o Tonsillectomy and Post-surgery ICU admission for HTN emergency & Atypical chest pain for 3 days . With c/o Diaphoresis headache palpitation refer to our hospital here CT Abdomen done s/o Right suprarenal region : 7.2 \*4.4\*5.4 cm mass .Without calcification .Left Adrenal Gland: 2 mass lesions (4.7×3.6×3.6 cm) (11×7 mm)

S/O: B/L ADRENAL MASSES

P/O ADRENAL PHEOCHROMOCYTOMA

After Clinical Diagnosis

Tab. Phenoxybenzamine (10mg ) BD Strated

After 4 days BP had :134/90 mmHg and tachycardia 100-110 bpm

Tab. Metoprolol (50) mg OD Added.

Patient posted for retroperitoneal laproscopic adrenalectomy.

### **Preoperative**

On examination patient was conscious, comfortable,

On examination vitals :

Sitting Pulse- 72/min

BP- 117/80 mm Hg

Supine Pulse- 77/min

BP- 110/70 mm Hg

Preoperative evaluation of ASA is classified as 1, airway assessment of Mallampati 2, and good mouth opening with appropriate neck motion.

Morning investigation : CBC , FBS

Morning medication :

Tab. Phenoxybenzamine (10mg)

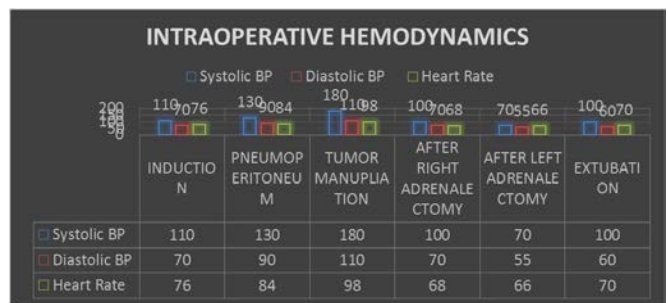
Tab. Metoprolol (50mg)

Written and informed high risk consent taken.

**Anxiolytic was given day before surgery.**

**Intraoperative**

In the operating room, ASA standard monitoring were connected, All emergency drugs were kept ready. Large bore iv cannula was secured. Inj. Midazolam iv was given before shifting to OT. Right Radial Artery secured - IBP monitoring. CVP guided crystalloid started. Vital parameters measured and recorded and also right internal jugular central line with central venous pressure monitoring Patient preoxygenated with 100% O<sub>2</sub> by face mask followed by induction of anesthesia using Fentanyl 100 mcg, Lignocaine 60 mg propofol 150 mg, and vecuronium 6 mg. Mask ventilation and intubation were easy. Inhaled sevoflurane was used initially.. Anesthesia was maintained with sevoflurane 2.5% in oxygen and air and vecuronium to maintain muscle paralysis. The patient was positioned in left lateral position with pressure points padded. Patient BP was stable during that time within the accepted range. With the pneumoperitonum BP start increases 130/90 mmhg , but BP kept fluctuating with manipulation of the mass and shooting to >180/110mmhg which controlled with 100 mcg nitroglycerine. After Right adrenalectomy bp maintaing around 100/70 so operating team decided to proceed for the left adrenalectomy . Here inj. Hydrocortisone 100 mg given . Patient position change to right lateral position. BP flautuation was minimum , after left adrenalectomy BP dropped to 80/60 mm hg vasopressor support started. Intra-operative urine output was adequate. Hourly sugar monitoring was done. Gradually vasopressor support was decreased and stopped before extubation. Patient was extubated uneventfully.



Post operatively patient shifted to HDU. Continue vitals (pulse , invasive BP , CVP , hourly sugar ) monitoring done. Inj. Diclofenac sodium for pain relief .Post-operative recovery was uneventful. Histopathology report confirmed the diagnosis of Pheochromocytoma.

**Discussion**

Adrenal gland is suprarenal gland. It is component of hypothalamo pituitary supra renal axis. It is retroperitoneal organ lie on upper poles of kidneys. It have two components : cortex and medulla . adrenal cortex (outer yellow ) produce steroid hormones and adrenal medulla (inner dark brown) produce adrenaline , nor adrenaline and dopamine<sup>[1]</sup>

Pheochromocytoma is tumour of adrenal gland. Incidence is 2-8 cases per million. It can occur between age of 20 to 50 years, also seen in children. It is secondary cause of hypertension in 0.1%. It is also part of multiple endocrine neoplasia<sup>[2]</sup> If it is diagnosed at induction of anesthesia , may cause hypertensive crisis and cause mortality upto 80%.

Pheochromocytoma ‘Rule of 10’

- 10% Extra-adrenal , 10% Occur in children, 10% Familial ,10% Bilateral or multiple ,10% Recur , 10% Malignant and 10% Discovered incidentally

Pheochromocytoma affect multisystem like in cardiovascular (arrhythmia, ST elevation or depression , MI , dialated cardiomyopathy , bundle branch block) , CNS ( stroke , encephalopathy) , Endocrine ( hyperglycemia , glucose intolerance ,hypercalcemia ,

lactic acidosis , thyrotoxicosis) , Respiratory (pulmonary edema).

Pheochromocytoma diagnosed by Urine test(24 hours urinary catecholamine level > 2 fold elevation , 24 hours urine metanephrine level >1.2mcg/dl , 24 hours VMA(vinyl mandelic acid) >3 folds elevation ) , Plasma test(plasma metanephrine>220 pg/ml , plasma normetanephrine>400 pg/ml and plasma catecholamine>2000 pg/m )<sup>[4]</sup> , location can be seen by CT scan , MRI.

Early diagnosis and definitive treatment with surgical resection is important because the tumour may be fatal if undiagnosed<sup>[7]</sup> Management of pheochromocytoma by surgical resection but prior to surgery , medical management should be done<sup>[5]</sup> Medical management include adrenergic blockers start to normalize blood pressure , heart rate and expand the contracted volume. Beta blockers should be started after adequate alpha blockade because of unopposed alpha blocker mediated vasoconstriction lead to hypertensive crisis<sup>[7]</sup>.

#### **Anaesthesia Goal**

Peri - Operative Hemodynamic Stability

- 1) Normalise Blood Pressure , Heart Rate & Function of other organs
- 2) Restore volume depletion
- 3) Prevent surgery induced catecholamine surge

Factors Increases Catecholamine Release:

Anxiety, Intubation ,Positioning ,Pneumoperitoneum andTumour manipulation

#### **Intra Operative Management**

IV sedation prior to shifting make it less prone to hypertensive crisis at induction. Smooth Induction & Laryngoscopy planned

For blunting stress response use Inj. Lignocaine 2% (1-1.5 mg /kg ), Inj. Esmolol (2-10 mg bolus ) or Inj. Fentanyl 2-5 mcg/kg

As During laryngoscopy and tracheal intubation catecholamine level increases

Normally :200-2000 pg/ml

Pheochromocytoma : 2000-20,000 pg/ml

Drugs (IV AGENTS) used to minimize hemodynamic response:

#### **Vasodilators**

Inj. Nitroglycerin (NTG)-Mainly affect Capacitance vessel ,Inj. Sodium Nitroprusside-Potent Arteriolar Dilator Rapid onset , Inj. Nicardipine - Inhibit Catecholamine release from adrenal medullary cells in vitro ,Inj. Diltiazem,Inj. Phentolamine- Reversible, shorter,Competitive alpha 1 & Weak alpha 2 blocker

Beta blocker

Inj. Esmolol Ultrashort acting beta 1 antagonist ,Inj. Labetolol alpha +beta blocker, Inj. Metoprolol or Inj. Atenolol

#### **Vasoconstrictors**

Inj. Noradrenaline Act on alpha receptor Increase peripheral vascular resistance & increases BP , Inj. Vasopressin ,Inj. Adrenaline ,Inj. Dobutamine ,Inj. Lignocaine 2%, Inj. Insulin ,Inj. D25%,Inj. DNS (500ml)

Inj. Magnesium sulphate

Inhibit catecholamine release from adrenal medulla .

Dexmedetomidine

Alpha 2 receptor agonist, Central sympatholytic effect cause reduction In plasma nor epinephrine level.

After tumour devascularisation

After adrenal vein ligation and removal of tumour, intra operative hypotension may occur because of Suppression of contralateral adrenal gland, Down regulations of adrenal gland , Effect of preoperative adrenoreceptor antagonist, sudden increase in venous capacitance.[7]

Anaesthetic management in bilateral resection of pheochromocytoma remains same except exaggerated fall in blood pressure may occur. Patient may develop vasoplegic shock and need vasopressin or methylene blue. Patient may need steroid replacement intra operatively. Reversal depend upon intraoperative course & postoperative state. Patient is shifted to HDU/under close monitoring<sup>[7]</sup>

### Postoperative Complications

Hypertension may be seen in 50% patients because of persistence of plasma catecholamine level.<sup>[6,7]</sup>

Hypotension may occur due to contra lateral adrenal, down regulation of adreno receptors, persistence effect of adrenergic blockade and intra abdominal bleed.<sup>[6,7]</sup>

Hypoglycemia may occur due to disappearance of pancreatic beta cell suppression, absence of Lipolysis, glycogenolysis, encephalopathy and glucose containing IV fluid started after tumour removal.<sup>[7]</sup>

### Conclusion

Long term outlook very good if managed by an experienced team of Anaesthesiologist, Surgeon and Endocrinologist.

Principles of anaesthetic management Good adrenergic blockade perioperative, vigilant intra op monitoring & treatment of hyper/hypotension AND post op ICU care

### Reference

1. Physiology, Adrenal Gland Meghan Dutt; Chase J. Wehrle; Ishwarlal Jialal Meghan Dutt<sup>1</sup>; Chase J. Wehrle<sup>2</sup>; Ishwarlal Jialal<sup>3</sup>.<sup>1</sup> California Northstate University Medical College of Georgia<sup>3</sup> VA Medical Center, Mather, CA
2. Barontini M, Levin G, Sanso G. Characteristics of pheochromocytoma in a 4- to 20-year-old population. Annals of the New York Academy of

Sciences. 2006;1073:30–37. [PubMed] [Google Scholar]

3. Jaroszewski DE, et al., Laparoscopic adrenalectomy for pheochromocytoma. Mayo Clin Proc. 2003;78:1501-4.
4. Unger N, Pitt C, Schmidt IL, Walz MK, Schmid KW, Philipp T, et al. Diagnostic value of various biochemical parameters for the diagnosis of pheochromocytoma in patients with adrenal mass. Eur J Endocrinol. 2006;154:409–17. [PubMed] [Google Scholar]
5. Garg MK, Kharb S, Brar KS, Gundgurthi A, Mittal R. Medical management of pheochromocytoma: Role of the endocrinologist. Indian J Endocrinol Metab. 2011;15 Suppl 4(Suppl4):S329-S336. doi:10.4103/2230-8210.86976
6. Pheochromocytoma resection: Current concepts in anesthetic management Harish Ramakrishna, Department of Anesthesiology, Division of Cardiovascular and Thoracic Anesthesiology, Mayo Clinic, Arizona, 5777 East Mayo Boulevard, Phoenix, AZ 85054, USA
7. Perioperative management of pheochromocytoma : Anaesthetic implication : Aliya Ahmed : Department of anaesthesia : Aga khan university Hospital: Karachi :vol57 :no.3 :March 2007 :140-145
8. Bilateral adrenal pheochromocytoma in a 10 year old male patient : HAGER ARIF :Journal of paediatric surgery case report : volume 2: issue 8: August 2014: 400-402
9. Karthickraja V, et al. Anaesthetic challenges for Laproscopic Bilateral Adrenalectomy in a rare case of cushing's syndrome – A case report. Med J Clin Trials case stud, 2018, 2(6):000189