

Optic neuritis: A visual field analysis

¹Dr. Rofadun Nisa, Department of Ophthalmology, Government Medical College, Srinagar, J&K, India.

²Dr. Afroz Khan, Department of Ophthalmology, Government Medical College, Srinagar, J&K, India.

Corresponding Author: Dr. Rofadun Nisa, Department of Ophthalmology, Government Medical College, Srinagar, J&K, India.

Citation this Article: Dr. Rofadun Nisa, Dr. Afroz Khan, “Optic neuritis: A visual field analysis”, IJMSIR- February - 2021, Vol – 6, Issue - 1, P. No. 165 – 168.

Type of Publication: Original Research Article

Conflicts of Interest: Nil

Abstract

Background: To study the visual field changes in patients of Optic Neuritis.

Design: Prospective study.

Material And Method: A prospective single institutional study was conducted on 52 eyes of 49 patients having Optic neuritis who underwent visual field analysis to study the changes in visual fields.

Results: The central/centrocecal field defect was seen in 53.8% (28 eyes) have central/centrocecal while 13.5% (07 eyes) have severely depressed fields. Enlargement of blind spot was seen in 11.5 % (06 eyes). Altitudinal and peripheral rim field defect was seen in 7.7% (04 eyes) each and arcuate in 5.8% (03 eyes).

Conclusion: Optic neuritis, as a harbinger of a more diffuse demyelinating process, merits careful attention to an exact diagnosis and a thorough consideration of treatment paradigms. Visual fields help quantify the depth of visual field loss, identify atypical cases of optic neuritis, and aid in counseling patients about prognosis.

Keywords: Optic neuritis, Visual field analysis, Central field defect, Centrocecal field defect.

Introduction

Optic neuritis is a term used to refer to inflammation of the optic nerve. When it is associated with a swollen optic disc, it is called papillitis or anterior optic neuritis. When the optic disc appears normal, the term retrobulbar optic neuritis or retrobulbar neuritis is used. In the absence of signs of multiple sclerosis (MS) or other systemic disease, the optic neuritis is referred to as monosymptomatic or idiopathic, or as a clinically isolated syndrome. The pathogenesis of isolated optic neuritis is presumed to be demyelination of the optic nerve, similar to that seen in MS. The pathogenesis of optic neuritis is not well understood. It is likely due to some inflammatory process which leads to delayed type IV hypersensitivity reaction induced by released cytokines and other inflammatory mediators from activated peripheral T-cells which can cross the blood brain barrier and cause destruction of myelin, neural cell death and axonal degeneration. Latest technologies such as optical coherence tomography (OCT) suggest involvement of axons (gray matter) in addition to myelin sheath (white matter) in this process.¹ It is likely that most cases of isolated acute optic neuritis are a forme fruste of MS. Optic neuritis usually is a primary

demyelinating process. It almost always occurs as an isolated phenomenon or in patients who either have, or will develop, MS. Patients in whom optic neuritis occurs as an isolated phenomenon have a higher risk of developing MS at some later date than the normal population. Optic neuritis is also part of the demyelinating syndrome called “neuromyelitis optica” or “Devic’s disease,” and it occasionally occurs in two other primary demyelinating diseases: myelinoclastic diffuse sclerosis (encephalitis periaxialis diffusa, Schilder’s disease) and encephalitis periaxialis concentrica (concentric sclerosis of Baló). There are three forms of primary demyelinating optic neuritis: acute, chronic, and subclinical. Retrobulbar neuritis and papillitis are mainly associated with MS while perineuritis and neuroretinitis are more often associated with infectious or inflammatory pathologies. Permanent visual loss (40% to 60%) and visual deficit in ON is a result of axonal loss in the optic nerve and retina and corresponding retinal nerve fiber layer (RNFL) thinning, in addition to conduction block caused by demyelination of the optic nerve.² In this study the most common visual field defect associated with Optic neuritis has been evaluated.

Material and Method

This is a prospective observational study that was conducted in Government Medical College, Srinagar, Department of Ophthalmology. In this study 52 eyes of 49 patients were included. After obtaining the ethical clearance from the ethical committee of the institution, the study was conducted for a period of two and half years from Aug., 2017- March, 2020. All patients with sudden unilateral or bilateral visual loss of less than a month, having RAPD or dyschromatopsia with swollen or normal optic disc were included in the study. The

patients with age less than 15 years and having ON due to any definite cause were excluded from the study.

The patients were diagnosed on the basis of characteristic history and clinical examination. Ophthalmic examinations including slit lamp examination and pupillary reactions (RAPD) were noted. Aided visual acuity was measured for distance vision by Snellen chart at 6m. Those unable to read any letters at one meter were further examined by counting fingers, identifying hand movements or perceiving light. Color vision, where visual acuity and central visual function allows, were recorded using Ishihara pseudoisochromatic color vision plates. Visual field determination, where aided visual acuity permitted, recorded for both eyes by Humphrey automated perimetry (Figure 1). Visual evoked potential was also done.

Neurological examinations including orbital and brain MRI was performed with gadolinium (Gd) preferably within two weeks after the onset of symptoms. Contrast enhancement of the optic nerve is a sensitive finding in acute Optic Neuritis but does not correlate with the degree of visual recovery.

The data was recorded in a spreadsheet (Microsoft Excel) and was sent for statistical analysis.

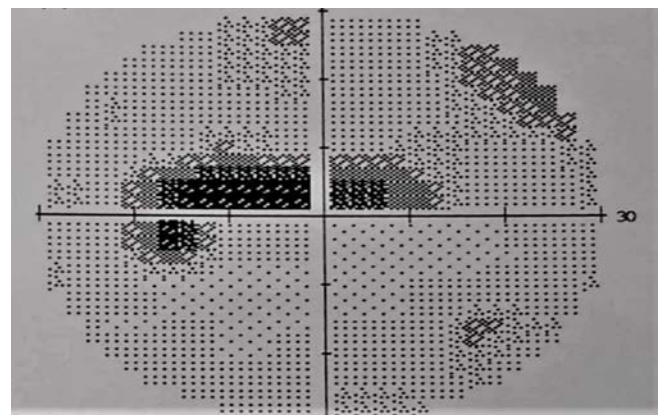
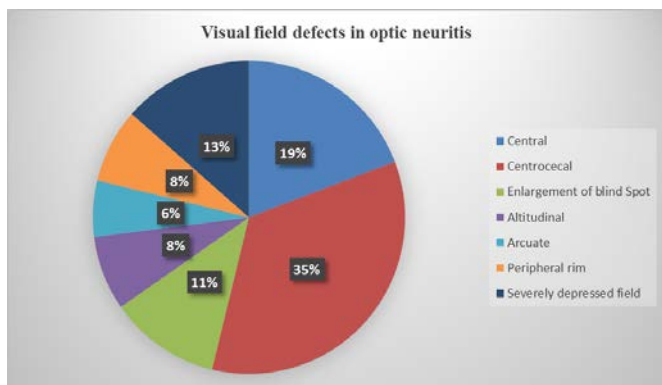


Figure 1: Central field defect in Optic neuritis.

Result

Field defect	Number of eyes	Percentage
Central	10	19.2
Centrocecal	18	34.6
Enlargement of blind spot	06	11.5
Altitudinal	04	7.7
Arcuate	03	5.8
Peripheral Rim	04	7.7
Severely depressed field	07	13.5
Total	52	100

Table 1: Visual field defects in Optic neuritis.



Graph 1: Visual field defects in Optic neuritis.

Table 1 and graph 1 shows that 53.8% (28 eyes) have central/centrocecal field defect, 13.5% (07 eyes) have severely depressed fields. Enlargement of blind spot was seen in 11.5 % (06 eyes). Altitudinal and peripheral rim field defect was seen in 7.7% (04 eyes) each and arcuate in 5.8% (03 eyes).

Discussion

Optic neuritis is, with the exception of glaucoma, the most frequent optic neuropathy encountered in general ophthalmic practice. The visual field defect is important not only in diagnosing optic neuritis but also in evaluating optic atrophy. Thus, if one is to decide

whether the "pallor" of a disc is physiological or pathological, the most reliable criterion lies in the study of the visual field. Thus, if a disc looks pale but complete field studies, including minimal testing of the central and peripheral fields and blind spots, give normal findings, one may safely say that the pallor is physiological. On the other hand, a field defect would indicate that the condition is true optic atrophy, and the type of field defect, coupled with the ophthalmoscopic picture and the clinical history, may well indicate the nature of the disease process having produced this atrophy.³ In majority of cases, the primary defect is a central scotoma that is more pronounced for colored than for white test objects and for red objects more than blue objects. In our study, the most common visual field defect was central/paracentral scotoma which was seen in 28 eyes. The severely depressed field was seen in 07 eyes while enlargement of blind spot was seen 06 eyes. Also, the arcuate visual field defect was present in 03 eyes while altitudinal and peripheral rim defect was seen in 04 eyes each. The study conducted by **Griffith AH**⁴ and **Gunn RM**⁵ revealed that the central field was always affected in patients with optic neuritis. Another study conducted by **Berliner MD**⁶ recorded typical central and paracentral defects in the study patients. **Carrol FD**⁷ revealed similar results. The ONTT documented that a variety of visual field abnormalities may be seen in patients with optic neuritis.⁸ The visual field defects found in the 448 patients enrolled in the ONTT were characterized as being "diffuse" or having specific patterns of visual field loss. The main patterns of visual field abnormality were as follows: • Diffuse: 48.2% • Localized defects, including altitudinal or other nerve fiber bundle defects: 20.1% • Central or centrocentral scotomas: 8.3% • Other: 23.2%. Among 100 patients with optic neuritis, **Chamlin M**³

found 44 patients with altitudinal visual field defects and 4 patients with peripheral defects. **Perkin GD et al**⁹ found only 31% of their patients to have pure central field defects.

Conclusion

Within the limitations of this study we can conclude that the central visual field loss occurs in majority of cases of optic neuritis.

Optic neuritis, as a harbinger of a more diffuse demyelinating process, merits careful attention to an exact diagnosis and a thorough consideration of treatment paradigms. Visual fields help quantify the depth of visual field loss, identify atypical cases of optic neuritis, and aid in counseling patients about prognosis.

References

1. Hoorbakht H and Bagherkashi F. Optic Neuritis, its Differential Diagnosis and Management. *Open Ophthalmol J.* 2012; 6: 65–72.
2. Pau D, Al Zubidi N, Yalamanchili S, Plant GT, Lee AG. Optic Neuritis Eye. 2011; 25(7):833–42
3. Chamlin, M. Visual field changes in optic neuritis. *Archives of Ophthalmology.* 1953; 50(6), 699–713.
4. Griffith AH. In discussion on retro-ocular neuritis. *Trans Ophthalmol Soc UK* 1897; 17:107–217.
5. Gunn RM. Discussion on retro-ocular neuritis. *Br MedJ* 1904; 2:1285–1287.
6. Berliner MD. Acute optic neuritis in demyelinating diseases of the nervous system. *Arch Ophthalmol* 1935; 13:83–98. 67.
7. Carroll FD. Retrobulbar optic neuritis: observations on one hundred cases. *Arch Ophthalmol* 1940; 24:44–54.
8. Keltner JL, Johnson CA, Spurr JO. et al. Baseline visual field profile of optic neuritis: the experience of the Optic Neuritis Treatment Trial. *Arch Ophthalmol* 1993, 111:231–234.
9. Perkin GD, Rose FC. *Optic Neuritis and Its Differential Diagnosis.* Oxford, UK, Oxford Medical Publications, 1979.