

**Modified Radical Mastectomy for Male Breast Cancer – A Case Report**

<sup>1</sup>Dr. Deepak G. Udupudi, Professor and Head of Department, Department of General Surgery, JJM Medical college and Bapuji hospital, Davangere-577004.

<sup>2</sup>Dr. Kailas C.T, Assistant Professor, Department of General Surgery, JJM Medical college and Bapuji hospital, Davangere-577004.

<sup>3</sup>Dr. Shweta D.Rao, Junior Resident, Department of General Surgery, JJM Medical college and Bapuji Hospital, Davangere-577004.

**Corresponding Author:** Dr. Shweta D. Rao, Junior Resident, Department of General Surgery, JJM Medical college and Bapuji Hospital, Davangere-577004.

**Citation this Article:** Dr. Deepak G. Udupudi , Dr. Kailas C.T, Dr. Shweta D.Rao, “ Modified Radical Mastectomy for Male Breast Cancer – A Case Report”, IJMSIR- August - 2020, Vol – 5, Issue - 4, P. No. 186 – 188.

**Type of Publication:** Case Report

**Conflicts of Interest:** Nil

**Abstract**

Male breast cancer (MBC) is a rare disease accounting for less than 1% of all breast cancer cases and less than 1% of all male cancers.<sup>1</sup> The traditional surgical management for male breast cancer is modified radical mastectomy (MRM). Other surgical methods such as breast conservation surgery with or without sentinel lymph node biopsy have been used with variable result<sup>2</sup>. We present a rare case of a 63 year old male with 3x3 cm painless breast lump over a period of one year. Trucut biopsy revealed Infiltrating ductal carcinoma. We performed MRM which is treatment of choice in MBC.

**Keywords:** Male breast cancer, Modified Radical Mastectomy, Axillary dissection, Adjuvant therapy.

**Introduction**

Male breast cancer accounts for less than 1% of all cancer in males. However, like female breast cancer, its incidence is on the rise. The median age of diagnosis of

breast cancer is around 67 years in males and 62 years in females.<sup>3</sup>

The typical presentation of male breast cancer consists of unilateral painless palpable lump in central subareolar location or eccentric to nipple-areolar complex.<sup>4,5</sup>

According to available literature, most cases of male breast cancer are invasive ductal carcinoma with estrogen and progesterone receptor positive states in 60-90% of the cases.<sup>6</sup>

For treatment of MBC, modified radical mastectomy is generally preferred to breast conservation surgery (BCS).<sup>7</sup> Some authors reported a more radical approach, 71% of the patients in Sanguinetti paper were treated with radical mastectomy.<sup>8</sup>

**Case Report**

A 62 year old with no family history of breast cancer, presented with a 6 month history of painless lump in the upper outer quadrant of the left breast. Patient gave no history of nipple discharge. He had no history of

radiation exposure or hormonal treatment. Physical examination revealed a breast lump 3x3 cm in size, in the upper outer quadrant of the left breast. No pathological lymph nodes were detected in the axilla at clinical and ultrasound examination. Trucut biopsy analysis revealed invasive ductal carcinoma with no special type (NOS), ER/PR +, Her-2 neu oncoprotein negative, KI-67 assay of 3-5%. The TNM staging was IIA (pT2NoMo) according to AICC guidelines.<sup>9</sup> A left modified radical mastectomy was performed. Histological examination was suggestive of Infiltrating ductal carcinoma (NOS Type). Adjuvant hormonal therapy was suggested to the patient. Goserlin acetate injection every 3 months for 2 years and Anastrozole tablets 1 mg OD for 5 years.

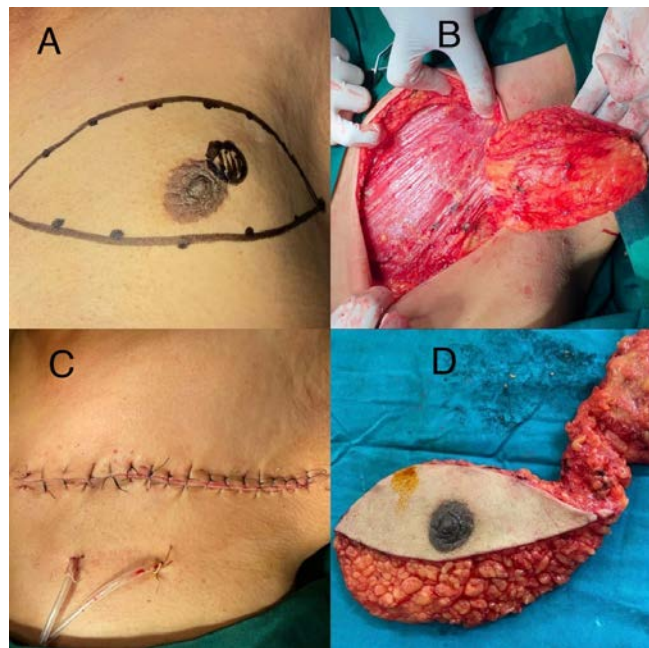


FIGURE 1.

- A. Location of breast lump in upper outer quadrant with marking of line of incision.
- B. Left MRM: Breast tissue detached from Pectoralis Major muscle.
- C. Closure of skin incision with vacuum drain in situ.
- D. Specimen of mastectomy.

## Discussion

Since there are no definite guidelines for the treatment of MBC, its treatment follows guidelines established for FBC. Modified Radical Mastectomy is the gold standard for treatment of MBC (70% cases), followed by radical mastectomy (8-30% cases) total mastectomy (5-14% cases) and lumpectomy with or without irradiation 1-13% cases).<sup>10</sup>

In selected patients with small tumours, or when MBC is associated with gynecomastia, breast conservation surgery followed by adjuvant therapy is advisable. Despite the current transition from radical to conservative surgical treatment of MBC, we maintain MRM is still regarded as the standard treatment of MBC due to paucity of male breast tissue, typical subareolar location of the tumour and debilitating effects of adjuvant therapy which is required with BCS. MBC is reported to have a higher positive rate of hormone receptor than FBC, so adjuvant hormonal therapy is theoretically promising.

## Conclusion

MBC remains a rare disease although its incidence is increasing. MBC tends to be diagnosed at an older age than FBC with later stage disease. Hence, we believe that modified radical mastectomy (MRM) with sentinel lymph node biopsy or axillary dissection should be considered as treatment of choice in MBC.

## Compliance with Ethical Standards

**Conflict of Interest:** The authors declare that they have no conflict of interest.

## References

1. J.M. Cloyd, T. Hernandez-Boussard, I.L. Wapnir Poor compliance with breast cancer treatment guidelines in men undergoing breast-conserving surgery Breast Cancer Res. Treat., 139 (1) (2013), pp. 177-182

2. B. Sousa, E. Moser, F. Cardoso An update on male breast cancer and future directions for research and treatment *Eur. J. Pharmacol.*, 717 (1–3) (2013), pp. 71-83
3. L. Ottini, D. Palli, S. Rizzo, *et al.* Male breast cancer *Crit. Rev. Oncol. Hematol.*, 73 (2) (2010), pp. 141-155
4. I.S. Fentiman, A. Fourquet, G.N. Hortobagyi Male breast cancer *Lancet*, 367 (9510) (2006), pp. 595-604
5. T.J. Tan, L.C. Leong, L.S. Sim Clinics in diagnostic imaging (147). Male breast carcinoma *Singapore Med. J.*, 54 (6) (2013), pp. 347-352
6. K.A. Johansen Taber, L.R. Morisy, A.J. Osbahr, *et al.* Male breast cancer: risk factors, diagnosis, and management (Review) *Oncol. Rep.*, 24 (5) (2010), pp. 1115-1120
7. S. Fogh, L.A. Kachnic, S.I. Goldberg, *et al.* Localized therapy for male breast cancer: functional advantages with comparable outcomes using breast conservation *Clin. Breast Cancer*, 13 (5) (2013), pp. 344-349
8. A. Sanguinetti, A. Polistena, R. Lucchini, M. Monacelli, S. Galasse, S. Avenia, *et al.* Male breast cancer, clinical presentation, diagnosis and treatment: Twenty years of experience in our Breast Unit *Int. J. Surg. Case Rep.*, 20S (2016), pp. 8-11
9. National Comprehensive Cancer Network (NCCN) Clinical practice guidelines in oncology Breast Cancer (2016)
10. B. Cutuli Strategies in treating male breast cancer *Expert Opin. Pharmacother.*, 8 (2) (2007), pp. 193-202